

## **7** Control of Parasites and Fungal Infections in Small Pet Mammals

ESCCAP Guideline 07 First Edition – July 2017

ESCCAP  
Malvern Hills Science Park, Geraldine Road, Malvern, Worcestershire WR14 3SZ

First Published by ESCCAP 2017

© ESCCAP 2017

All rights reserved

This publication is made available subject to the condition that any redistribution or reproduction of part or all of the contents in any form or by any means, electronic, mechanical, photocopying, recording, or otherwise is with the prior written permission of ESCCAP.

This publication may only be distributed in the covers in which it is first published unless with the prior written permission of ESCCAP.

A catalogue record for this publication is available from the British Library.

ISBN: 978-1-907259-39-5

## TABLE OF CONTENTS

INTRODUCTION	4
CONSIDERATION OF PET HEALTH AND LIFESTYLE FACTORS	5
<b>CHAPTER 1:</b> COMMON OR IMPORTANT PARASITES AND FUNGAL INFECTIONS OF RABBITS	7
<b>CHAPTER 2:</b> COMMON OR IMPORTANT PARASITES AND FUNGAL INFECTIONS OF RATS	17
<b>CHAPTER 3:</b> COMMON OR IMPORTANT PARASITES AND FUNGAL INFECTIONS OF MICE	25
<b>CHAPTER 4:</b> COMMON OR IMPORTANT PARASITES AND FUNGAL INFECTIONS OF GERBILS	33
<b>CHAPTER 5:</b> COMMON OR IMPORTANT PARASITES AND FUNGAL INFECTIONS OF GUINEA PIGS	39
<b>CHAPTER 6:</b> COMMON OR IMPORTANT PARASITES AND FUNGAL INFECTIONS OF HAMSTERS	49
<b>CHAPTER 7:</b> COMMON OR IMPORTANT PARASITES AND FUNGAL INFECTIONS OF CHINCHILLAS	59
<b>CHAPTER 8:</b> COMMON OR IMPORTANT PARASITES AND FUNGAL INFECTIONS OF FERRETS	65
Appendix 1 — Background	73
Image Acknowledgements	73

## Control of Parasites and Fungal Infections in Small Pet Mammals

ESCCAP Guideline 07 First Edition – July 2017

## INTRODUCTION

In common with larger mammals, parasites can cause considerable disease and suffering in small pet mammals. This guideline provides information on common or important parasites and fungal infections known to affect small pet mammals in Europe. It examines the risks to the host and provides guidance on control, which often depends on a combination of management and drug treatment.

The list of parasites and fungal infections included in this guideline is not exhaustive but does include the most common and those that are pathogenic in Europe.

Few licensed treatments exist for parasitic and fungal infections in small pet mammals therefore many preparations are used off-label. In some European countries, exemptions for the use of non-licensed products may apply. In countries where such exemptions are not in place, it is a veterinary decision which drugs to use if there are no licensed treatments available.

Where possible, a licensed treatment is mentioned, however many of the suggested prophylactic or therapeutic treatments are unavoidably based on medicines unlicensed for small pet mammals. In contrast, lists of specific treatments available for cats and dogs in individual European countries are available on the ESCCAP national association websites.

Where there are zoonotic implications, they have been discussed in the text. It is important to minimise human exposure to potentially contaminated environments and to implement good hygiene practices. Anyone who is immunocompromised or suffering from an existing illness should be advised of the health risks of such human–animal contact.

A number of specialised publications are available on diseases affecting small pet mammals including parasitic and fungal diseases. Further reading suggestions may be available through ESCCAP national associations.

## CONSIDERATION OF PET HEALTH AND LIFESTYLE FACTORS

Animals require care tailored to their individual needs. Certain factors may dictate more intensive monitoring and/or treatment, while others may suggest a less aggressive approach.

### Animal

The age and health status of the animal are important, including its history and origin. Some small pet animal species have a greater susceptibility to some diseases, while other concomitant infections may predispose to or aggravate existing parasitic or fungal diseases.

### Environment

Animals kept in groups or those living outdoors may be at greater risk of acquiring infections than individual animals living indoors. Also there may be cross-infection of some parasites and dermatophytes between small mammals living in households with other domestic animal pets. The risk of transmission may also depend on various local conditions such as geographical areas where certain parasitic diseases are endemic. Owners should practise good husbandry and ensure that cage sizes are adequate and bedding quality is appropriate for the species. Animals should be housed in a well-ventilated, dry and draught-free area protected from temperature extremes.

### Hygiene

Maintenance of good hygiene standards is important as is treatment of the environment in some cases. This includes keeping cages or hutches clean and frequently changing bedding to eliminate possible sources of reinfestation. Most small pet mammals kept in unhygienic conditions may be susceptible to blowfly strike and maggots.

### Nutrition

Poor nutrition may contribute to an animal's susceptibility to many diseases including parasitic and fungal infections. A good quality diet and vitamin and mineral supplementation is recommended and considered important in aiding recovery.

### Location and Travel

Animals living in, or travelling to, endemic areas are at a higher risk of acquiring certain infections. Extra care should be taken when taking animals on holiday, to shows or if they are re-homed or placed in boarding facilities.



## **1: Rabbits**

Common or important parasites and fungal infections



CHAPTER 1:  
COMMON OR IMPORTANT PARASITES AND  
FUNGAL INFECTIONS OF RABBITS

This chapter does not deal with rabbits kept for food production where regulations are in place concerning management and treatment.

PARASITES	INTERNAL	
	Roundworms	<i>Passalurus ambiguus</i> , <i>Obeliscoides cuniculi</i> , <i>Graphidium strigosum</i> , <i>Trichostrongylus retortaeformis</i>
	Adult Tapeworms	<i>Cittotaenia ctenoides</i> , <i>Mosgovoyia pectinata</i>
	Tapeworm Larvae	Alveolar hydatid cysts ( <i>Echinococcus multilocularis</i> ), larval stage of <i>Taenia pisiformis</i> (cysticercus pisiformis), larval stage of <i>Taenia serialis</i> (coenurus serialis)
	Protozoa	<i>Eimeria</i> spp., <i>Giardia</i> spp., <i>Toxoplasma gondii</i>
	EXTERNAL	
	Fleas	<i>Spilopsyllus cuniculi</i> , <i>Ctenocephalides</i> spp.
	Flies	<i>Lucilia sericata</i> and others
	Lice	<i>Haemodipsus ventricosus</i>
	Mites	<i>Cheyletiella parasitivorax</i> , <i>Psoroptes cuniculi</i> , <i>Leporacarus gibbus</i> , <i>Demodex cuniculi</i> , <i>Sarcoptes scabiei</i> , <i>Notoedres cati</i> , <i>Ornithonyssus bacoti</i>
FUNGAL INFECTIONS	Ticks	<i>Ixodes</i> spp. and other Ixodidae
	INTERNAL	
	Systemic	<i>Encephalitozoon cuniculi</i> , <i>Pneumocystis oryctolagi</i>
	EXTERNAL	
	Dermatophytes	<i>Trichophyton mentagrophytes</i> (complex species), <i>Microsporum canis</i>

INTERNAL PARASITES

Roundworms

Rabbits can become infected with a variety of worms and in many cases the adult worms are found in the gastrointestinal tract.

Nematodes known to infect rabbits include *Passalurus ambiguus* (Fig. 1). This is an oxyurid (or pinworm) commonly found in the caecum and large intestine of (domestic) rabbits. The presence of even relatively large numbers of pinworms is nonpathogenic. The adult worms measure up to 1 cm in length. Occasionally, some infections by *P. ambiguus* can cause rectal, anal and perianal irritation, rectal prolapse, restlessness and decreased weight gain. Diagnosis is by adhesive tape method or (rarely) coproscopy. Eggs are typically flattened along one side as for most oxyurid species.

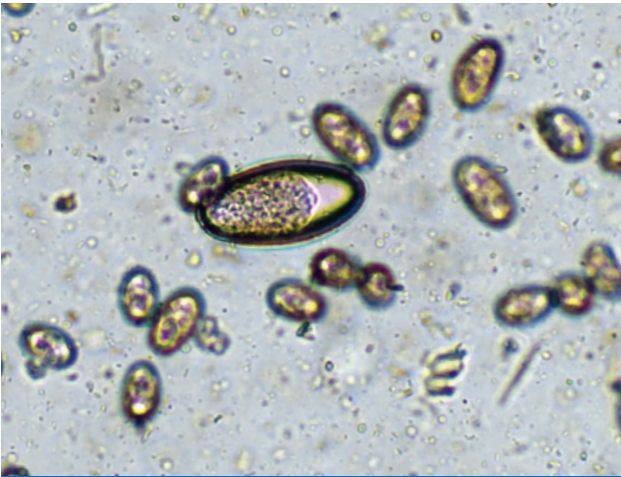

Fig. 1: *Passalurus ambiguus* egg seen with *Eimeria* spp.

*Obeliscoides cuniculi*, *Graphidium strigosum* and *Trichostrongylus retortaeformis* are the most common species of gastrointestinal nematodes in wild rabbits, all with direct life cycles. In domestic rabbits, they are rarely found.

## Tapeworms

The adult stage of several species of tapeworm can occur in the intestine of rabbits including *Cittotaenia ctenoides* and *Mosgovoyia pectinata*. They occur predominantly in wild rabbits but can occasionally be found in domestic rabbits. All have an indirect life cycle with free-living mites and other invertebrates as intermediate hosts.

Rabbits can harbour the cystic stages of several adult tapeworms of dogs, the most common being *Taenia pisiformis* and *Taenia serialis*. The former causes liver, peritoneal or retrobulbar cysts (cysticercus pisiformis) and the latter cystic lesions in muscle and subcutaneous tissue (coenurus serialis). These cysts rarely cause health problems but can be surgically removed if necessary. Domestic rabbit infections originating from egg contamination from the faeces of urban foxes and other carnivores have been increasingly reported.

## Protozoa

There are a number of *Eimeria* species that infect rabbits. Of them, *Eimeria intestinalis* (Fig. 2) and *Eimeria flavescens* are the most pathogenic intestinal species. *Eimeria stiedai* infects bile duct epithelial cells causing hepatic coccidiosis. In all cases, infection is transmitted by environmentally-resistant oocysts passed in the faeces of infected rabbits. *Eimeria* may be mistaken for the yeast *Cyniclomyces guttulatus* (Fig. 3).

Infection with *Eimeria* species is most likely to be a problem where large numbers of rabbits are kept in close proximity, however, infection may also occur in pet rabbits. In conditions favourable for oocyst survival, high levels of infection can build up. Infection is most likely to cause clinical signs in young rabbits but after an initial infection they often acquire immunity to subsequent infection.

Intestinal coccidiosis may result in chronic diarrhoea, weight loss and reduced appetite. Consequences of hepatic coccidiosis include diarrhoea, weight loss, jaundice, hepatomegaly and ascites. The severity of these clinical signs will depend on the *Eimeria* species involved, level of infection and the immune status of the animal. Infections can occur if a pet rabbit comes into contact with an *Eimeria* species for which it has no immunity. Patent infections can be diagnosed by the detection of oocysts in the faeces.

*Giardia* spp. infect the small intestine of rabbits and *Giardia* cysts (8–10 µm) can be found in the faeces. The clinical significance of infection is unknown and, at present, it is unclear whether *Giardia* spp. from rabbits belong to a zoonotic assemblage.

Rabbits can act as intermediate hosts for *Toxoplasma gondii*. Infection is usually asymptomatic but can also cause granulomatous inflammation in a wide variety of organs including the central nervous system (CNS). Contact with infected rabbits does not represent a risk for pet owners.

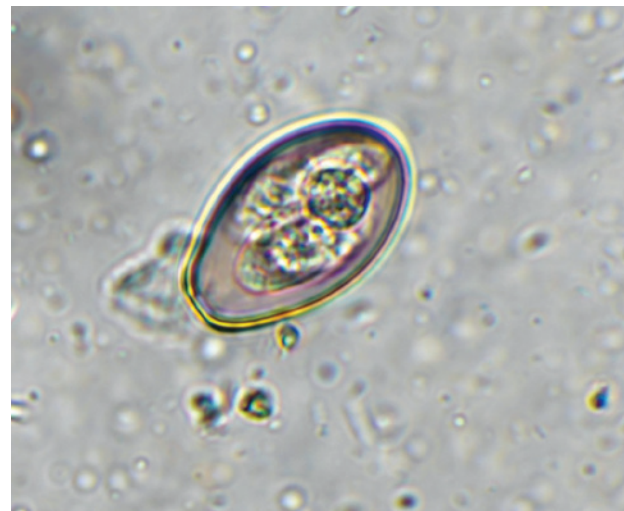

Fig. 2: *Eimeria intestinalis* oocyst (27 x 18 µm)

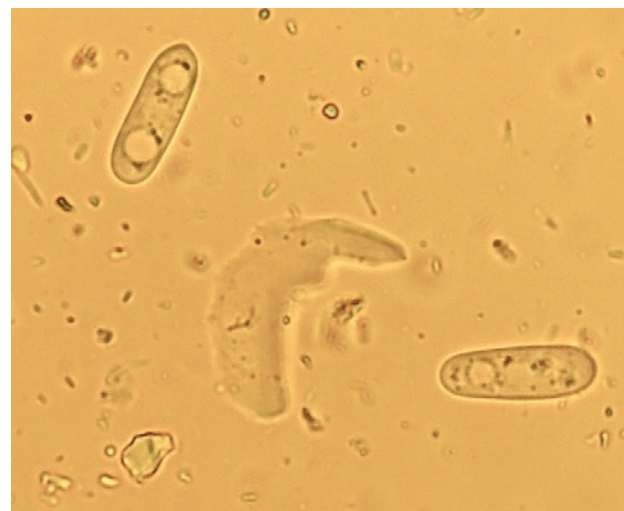

Fig. 3: *Cyniclomyces guttulatus* (8–10 µm in length)

## EXTERNAL PARASITES

### Fleas

Wild rabbits and domestic rabbits that live in close contact with wild rabbits may be infested with the rabbit flea *Spilopsyllus cuniculi*. These fleas attach around the pinnae and tend not to move even when handled. *Spilopsyllus cuniculi* fleas are vectors of myxomatosis (as are mosquitoes).

Rabbits, particularly those living in a household with dogs and cats, may become infested with the dog or cat flea (*Ctenocephalides* spp.). These fleas can be found on the body of the rabbit and infestation can be associated with considerable irritation. As with cats and dogs, diagnosis is based on the demonstration of fleas or flea faeces using a flea comb.

### Flies

*Lucilia sericata* and other flies may cause fly strike (myiasis) in hot summer months. Female blow flies lay their eggs in wounds or soiled areas of the coat; they are particularly attracted to areas soiled by urine or faeces. Once hatched, the larvae or maggots begin to feed in the skin and within a relatively short time they may penetrate subcutaneous tissues. Affected rabbits rapidly become depressed and infection can prove fatal unless treated promptly. Diagnosis is based on the demonstration of maggots on the skin.

### Lice

*Haemodipsus ventricosus* lice are rare parasites in domestic rabbits. Animals can become infested by lice if kept under poor husbandry conditions and may show irritation, suffer slight hair loss and/or become anaemic. Diagnosis is based on the demonstration of lice on the coat or egg cases (nits) in fur samples.

### Mites

The fur mites *Cheyletiella parasitivorax* and *Leporacarus gibbus* can be well tolerated in rabbits but may also be associated with skin irritation, slight hair loss and a scaly dermatitis, usually along the back of the animal. These non-burrowing mites are relatively large, visible to the naked eye and may cause movement of skin scales. This can be seen on close examination of the coat as 'walking dandruff'. Diagnosis is based on microscopic identification of mites on fur samples (Fig. 4). *Cheyletiella parasitivorax* can be transferred to humans by handling infected rabbits causing irritation and skin lesions.

*Psoroptes cuniculi* is a surface mite that occurs most commonly in the external ear canals and the pinnae of rabbits causing a thick, scaly lesion known as an ear canker (Fig. 5). The lesions are pathognomonic of disease and mites may be seen on microscopic examination.

*Demodex cuniculi* is a relatively rare parasite of the domestic rabbit. Infestations cause moderate pruritus and scaly skin lesions — signs similar to those seen in cheyletiellosis.

The burrowing mites *Sarcoptes scabiei* and *Notoedres cati* can cause scabies in rabbits. Affected animals experience mild pruritus and show typical skin changes including hyperkeratosis, excoriations and scaly crusts on the head, ears, distal limbs and interdigital areas. Both species are zoonotic and can cause skin irritation to the handler, however the life cycle of these mites is self-limiting as it cannot be completed in humans. This is also true for *Cheyletiella*.

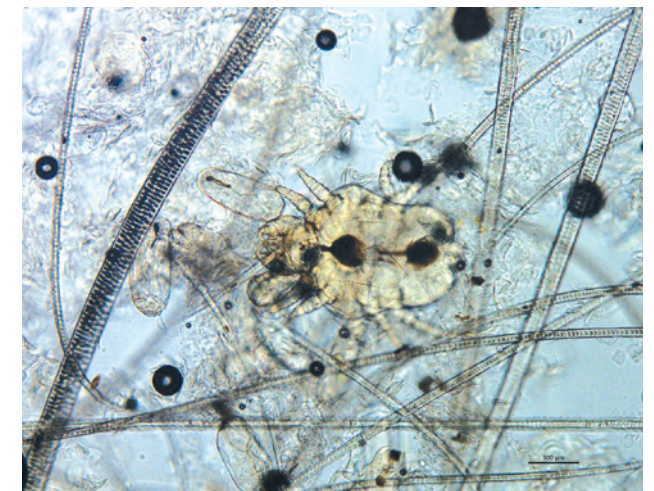


Fig. 4: *Cheyletiella parasitivorax*

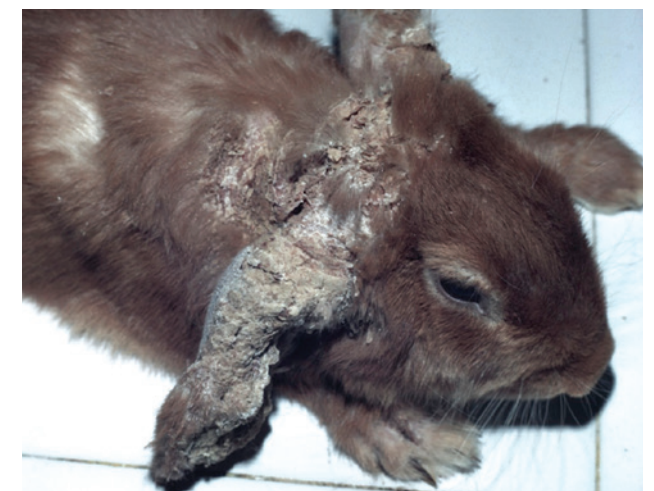


Fig. 5: Psoroptic mange




The tropical rat mite (*Ornithonyssus bacoti*) is worldwide in distribution and primarily affects wild rodents such as rats and mice (Fig. 15). However, small, domestic mammals including rabbits can also be possible reservoirs. The blood-feeding mites, which can cause skin irritation and anaemia, are active at night and seek dark hiding places during the daytime. A definitive diagnosis requires the detection of the parasite, which is more likely to be found in the environment (e.g. in cages, in litter and in corners or cracks of the living area) than on the host's skin itself. In the case of close human–pet contact, mites can occasionally cause pruritic dermatitis in humans.

#### Ticks

Ixodid ticks can affect rabbits if they live outside. These ticks will feed for several days before they drop off naturally. They may be removed with a tick removal tool.

### INTERNAL FUNGAL INFECTIONS

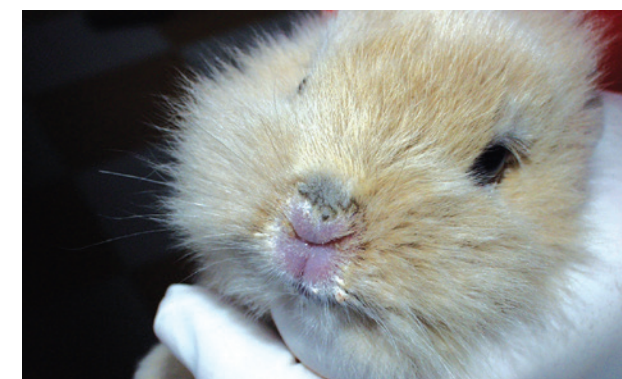*Encephalitozoon cuniculi* is an intracellular microsporidial parasite. Infection can be asymptomatic but mild to severe neurological consequences may result. The CNS, kidney and eye are predilection sites for the organism. There is evidence to suggest that up to 50% of rabbits are seropositive. Neurological signs, for example head tilt (Fig. 6), ataxia and paralysis, or other signs such as uveitis, symptoms of nephritis and emaciation resulting in death may be seen in infected rabbits. Transmission occurs via spores which are passed in the urine from approximately one month after initial infection. A tentative diagnosis is based upon history, clinical signs, serology and, although rarely detected, the demonstration of spores in the urine. *E. cuniculi* is considered to be one of the most virulent microsporidial organisms to infect humans although disease accompanied by clinical signs is rare in healthy individuals but can occur in immunocompromised patients.



*Pneumocystis* spp. may be commensal inhabitants of the lungs of rabbits. These atypical fungal organisms are highly host-specific. *Pneumocystis oryctolagi* has been described in rabbits. Secondary interstitial pneumonia may occur when the animals are immunosuppressed or debilitated owing to concurrent disease. Pneumocystosis may also be observed at weaning in rabbits.

### EXTERNAL FUNGAL INFECTIONS

Most cases of ringworm in rabbits are due to infection with dermatophytes which belong to the complex species *Trichophyton mentagrophytes*, although some (<5%) are caused by *Microsporum canis*. Transmission occurs through direct contact between animals or indirectly through a contaminated environment. Fungal spores are highly resistant in the external environment and young animals are particularly prone to disease. Lesions, mostly seen in young rabbits, begin with broken hairs and circular, scaly alopecia, typically at the base of the ears and muzzle (Fig. 7). Diagnosis is confirmed by microscopic demonstration of arthrospores in skin scrapings (KOH method) or by mycological cultures.



Ringworm is readily transmitted by fungal spores on grooming equipment or in bedding. If infection is suspected, the use of shared grooming equipment should be avoided. Spores will remain viable in hutches for years therefore thorough disinfection is essential after an outbreak to eliminate the fungus. Ringworm is fairly common in rabbits and poses a zoonotic risk to anyone handling infected animals. Because of the zoonotic potential, gloves should be worn whilst handling infected animals and when cleaning the environment. Bedding, in such situations, should be burned.

### TREATMENT OF PARASITE AND FUNGAL INFECTIONS

There are relatively few anti-parasitic drugs licensed for therapeutic use in rabbits and these are reviewed in this section. A large number of drugs are used off-label.

#### Roundworms

Fenbendazole at 5–20 mg/kg bodyweight orally for 5 days and repeated after 14 days if necessary is recommended for the treatment and control of gastrointestinal worms. For *Passalurus ambiguus* infection, the higher dose of 20 mg/kg bodyweight may be required.

Other effective anthelmintic compounds are available in many different formulations. These could be used in rabbits with the same recommended dosages as for other domestic animals.

#### Tapeworms

Praziquantel is the drug of choice in treating tapeworm infection in small pet mammals. The drug can be provided at a single oral dose of 10 mg/kg bodyweight and repeated after 10 days, if needed.

#### Protozoa

A number of anti-coccidials may be used off-label when necessary. For example, toltrazuril 2.5–5 mg/kg bodyweight, administered orally for 3–5 days has been recommended. Alternatively, toltrazuril can be administered through the drinking water or given orally at a dose of 25 mg/l or 10–25 mg/kg for two days and repeated after 5–7 days at times of increased risk of exposure to infection such as during exhibitions or shows. Sulphonamides can also be used e.g. the combination trimethoprim plus sulfamethoxazole at a dosage of 30–40 mg/kg bodyweight orally twice daily. Care should be taken when using these drugs in animals showing signs of liver damage.

#### Fleas

Imidacloprid (single dose of 10–16 mg/kg topically) is indicated for the treatment of flea infestations in pet rabbits. Selamectin (8–20 mg/kg topically every 7–30 days), permethrin and deltamethrin preparations may also be used for the control of fleas. Fipronil and pyriprole should not be used in rabbits as its administration has been associated with neurologic disease and death. As well as treating the animal, it is also important to treat the environment.

### Other Ectoparasites

Permethrin may be used to treat/control flies, ticks and lice. The macrocyclic lactones ivermectin (0.2–0.4 mg/kg bodyweight subcutaneously every 10–14 days), doramectin (0.2–0.3 mg/kg bodyweight subcutaneously/intramuscularly as a single dose), moxidectin (0.2–0.3 mg/kg orally/subcutaneously, repeated after 10 days if needed) and selamectin are suitable for the treatment and control of lice and fur, ear and mange mites in rabbits. In some countries, ivermectin spot-on is available for use in rabbits and other small mammals. Dosage and treatment frequency should be in accordance with the manufacturer's instructions. In the case of *Psoroptes cuniculi* infection, the abundant cerumen should be removed and the ears must be cleaned with a mild antiseptic prior to the administration of these drugs.

Nitenpyram, reported by veterinarians and wildlife rehabilitators to kill blowfly maggots in mammals and birds, has anecdotally been reported as effective in rabbits. To alleviate the shock associated with blowfly strike, pain relief is recommended.

### Fungal Infections

Fenbendazole is recommended for the treatment of *Encephalitozoon cuniculi* infection when administered at an oral dosage of 20 mg/kg bodyweight daily for 28 days. It can assist in reducing the severity of the clinical signs but elimination of the infection is not possible.

For fungal infections, a combination of systemic and topical treatment is recommended. Systemic treatment relies on the daily administration of an oral antifungal drug: griseofulvin (25–50 mg/kg bodyweight – this can be given in two daily doses), itraconazole (2.5–10 mg/kg bodyweight) or terbinafine (8–20 mg/kg bodyweight). The decision to use topical therapy with enilconazole or miconazole should be based upon the owner's ability and willingness to pour or sponge the product over the entire coat of the infected animal. The frequency of topical treatment should be at least twice a week. When sponging or bathing, the owner needs to consider hypothermia and the animal should be dried carefully. Ointments, creams, lotions or shampoos containing miconazole can also be used on localised lesions, but on a daily basis.

Owners are advised to stop antifungal administration after two negative mycological cultures. Hygiene measures are extremely important, especially treatment of the environment. For large groups of affected rabbits, the environment can be sprayed with an enilconazole solution of 50 mg/m<sup>2</sup> twice weekly for 4 months. Additionally, the rabbit owner should use disposable gloves and thoroughly wash/disinfect clothes and shoes after every treatment and/or animal manipulation.

## PREVENTION OF PARASITE AND FUNGAL INFECTIONS

Prevention of parasite infection generally involves a combination of good environmental management and prophylactic drug treatments.

For example, quarantine should be initiated for animals of unknown history before mixing with resident animals and high standards of husbandry should be maintained with particular attention to feed and bedding. Dogs with access to areas grazed by rabbits should be regularly treated for tapeworms to avoid infecting the rabbits with tapeworm cysts.

Although good environmental management strategies will prove beneficial, the number of licensed drugs available for either the prophylactic or therapeutic treatment of rabbits remains limited.

Coccidiosis is unlikely to be a problem for well-managed, small-scale rabbit keepers. Daily cleaning of cages and materials is advised to prevent environmental contamination with oocysts. Mixing rabbits which may be carrying different strains should be avoided.

Fenbendazole may be used for the prevention of *Encephalitozoon cuniculi* infection when administered at an oral dose of 20 mg/kg bodyweight for 7–14 days 4 times a year. This preventative treatment may be used at times of increased risk of exposure to infection such as exhibitions or shows. Stressful situations can also induce shedding and flare-ups of an existing infection. Prolonged use of fenbendazole in rabbits can be associated with bone marrow suppression.

Various compounds marketed for the prevention of blowfly strike in sheep may be used in rabbits e.g. dicyclanil and cyromazine. These can prevent fly strike for up to 16 weeks after application. Protection from blowfly strike may be achieved by bringing rabbits indoors and keeping their coats clean, especially during periods of warm, humid weather.

### Disclaimer:

*Every effort has been taken to ensure that the information in the guideline, which is based on the authors' experience, is accurate. However the authors and publishers take no responsibility for any consequence arising from the misinterpretation of the information herein nor is any condition or warranty implied. ESCCAP emphasises that national, regional and local regulations must be borne in mind at all times before following ESCCAP advice. All dosages and indications are provided for guidance. However, vets should consult individual data sheets for details of locally approved treatment regimen.*





## 2: Rats

Common or important parasites and fungal infections

CHAPTER 2:

COMMON OR IMPORTANT PARASITES  
AND FUNGAL INFECTIONS OF RATS

PARASITES	INTERNAL	
	Roundworms	<i>Heligmosomoides polygyrus</i> (syn. <i>Nematospiroides dubius</i> ), <i>Nippostrongylus</i> spp., <i>Trichostrongylus</i> spp., <i>Heterakis spumosa</i> , <i>Calodium hepaticum</i> (syn. <i>Capillaria hepatica</i> ), <i>Trichosomoides crassicauda</i> , <i>Syphacia muris</i> , <i>Aspiculuris tetraptera</i> , <i>Moniliformis moniliformis</i> , <i>Trichuris muris</i>
	Adult Tapeworms	<i>Rodentolepis nana</i> (syn. <i>Hymenolepis nana</i> ), <i>Hymenolepis diminuta</i> , <i>Cataenotaenia pusilla</i>
	Tapeworm Larvae	Larval stage of <i>Taenia taeniaeformis</i> (cysticercus fasciolaris)
	Protozoa	<i>Giardia</i> spp., <i>Chilomastix</i> spp., <i>Trichomonas</i> spp., <i>Entamoeba muris</i> , <i>Trypanosoma lewisi</i> , <i>Spironucleus muris</i> , <i>Eimeria</i> spp., <i>Cryptosporidium</i> spp., <i>Sarcocystis</i> spp., <i>Toxoplasma gondii</i> , <i>Babesia microti</i>
	EXTERNAL	
	Fleas	<i>Nosopsyllus fasciatus</i> , <i>Xenopsylla</i> spp., <i>Ctenocephalides</i> spp.
	Lice	<i>Polyplax spinulosa</i>
	Mites	<i>Myobia musculi</i> , <i>Myocoptes musculus</i> , <i>Radfordia</i> spp., <i>Notoedres muris</i> , <i>Trixacarus diversus</i> , <i>Demodex ratticola</i> , <i>Psorergates simplex</i> , <i>Ornithonyssus bacoti</i> , <i>Liponyssoides sanguineus</i>
	Ticks	<i>Ixodes</i> spp. and other Ixodidae
FUNGAL INFECTIONS	INTERNAL	
	Systemic	<i>Encephalitozoon cuniculi</i> , <i>Pneumocystis</i> spp.
	EXTERNAL	
	Dermatophytes	<i>Trichophyton mentagrophytes</i> (complex species), <i>Microsporum</i> spp.

INTERNAL PARASITES

Roundworms

Pinworms (*Syphacia muris*, *Aspiculuris tetraptera*) have a direct life cycle; they feed on bacteria in the intestinal tract and are usually non-pathogenic, even in large numbers. Occasionally, *Syphacia* can cause rectal, anal and perianal irritation, rectal prolapse and decreased weight gain. Debilitated animals are more susceptible to other infections. Diagnosis is by adhesive tape method or (rarely) coproscopy. Eggs are typically flattened along one side.

*Trichosomoides crassicauda* is a nematode found in the epithelium and lumen of the urinary bladder of wild rats. *Capillaria*-like eggs are shed in the urine. Clinical signs are associated with the larvae which migrate through the lungs and kidneys causing inflammation and granulomatous reactions.

Trichuris muris is a nematode of the large intestine, commonly known as whipworm. It is mostly associated with wild rats and mice but can also be found in domestic equivalents. Clinical signs can include mucoid diarrhoea with blood staining. Eggs can be isolated by centrifugal/flotation techniques. They are barrel or lemon-shaped, light brown in colour and show bipolar plugs.



### Tapeworms

The small tapeworms (*Rodentolepis nana*, *Hymenolepis diminuta*) may be found in the lumen of the small intestine of many mammalian hosts, including rats. The parasite is transmitted directly via eggs or through ingestion of an intermediate host. With the auto-infective cycle, eggs mature within the intestinal lumen without leaving the host. Infection levels depend on the quality of husbandry. Eggs in a contaminated environment may cause zoonotic infections, especially in children. Strict hygiene, such as thorough cleaning and sterilisation, is needed. Normally the infection causes little harm in rats. Diagnosis is made by faecal examination and by the demonstration of typical thick-walled, round eggs containing an embryo with six hooklets (Fig. 8).

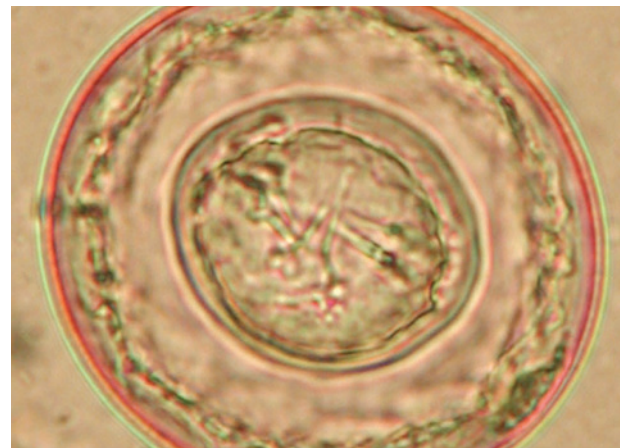


Fig. 8: *Rodentolepis/Hymenolepis* egg (60 x 80 µm)

### Protozoa

Flagellates of the genus *Giardia* are common intestinal parasites in rodents and rats may be infected by *Giardia intestinalis* or *G. muris*. Trophozoites attach to the mucous membrane of the intestinal villi. *Giardia* cysts (8–10 µm) can be seen in faecal samples. Infections are often subclinical but can result in diarrhoea and weight loss.

The coccidia of the genus *Eimeria* are often considered non-pathogenic or secondary pathogens in rodents and the rat is the host of several species, two of which are found in the small intestine (*E. nieschulzi* and *E. miyairii*) and one in the caecum (*E. separata*). *Eimeria nieschulzi* is the most commonly found and potentially the most pathogenic. It affects mostly young animals in which heavy infection may be fatal. Diagnosis is by faecal examination (typical oocysts can be detected) or by post-mortem examination showing enteric thickening and petechial haemorrhages.

Cryptosporidiosis occurs in a large variety of hosts including rodents, frequently causing diarrhoea. Polymerase chain reaction-based genotyping (PCR) and subtyping tools have allowed the identification of several *Cryptosporidium* species (including *C. parvum*, *C. muris*, *C. andersoni* and *C. wrairi*) and nearly 20 genotypes of uncertain species status in rodents worldwide. Mixed *Cryptosporidium* species/genotypes are also sometimes detected. The organisms are found within epithelial cells of the stomach or intestine. Clinical signs are associated with subsequent villous atrophy and enteritis, which may lead to unthriftiness, weight loss, diarrhoea and death. *Cryptosporidium* oocysts are very small (approximately 4–5 µm) but can be detected by modified acid-fast staining of fresh faecal samples.

Rats can act as intermediate hosts for *Toxoplasma gondii*. The infection is acquired through the ingestion of sporulated oocysts from cats or through vertical transmission via the placenta during pregnancy. The pathogenicity of the infection depends on the number and virulence of the infecting organisms. Infections are usually asymptomatic but can cause granulomatous inflammation in a wide variety of organs. Contact with infected rats does not represent a risk for pet owners.

## EXTERNAL PARASITES

### Fleas

Wild rats are the preferred hosts of fleas of the genera *Nosopsyllus* (Fig. 9) and *Xenopsylla*, whereas fleas of the genus *Ctenocephalides* are often found infesting pet rats housed near cats and/or dogs. Flea infestation is associated with a dull coat, alopecia and pruritus. Secondary bacterial infection, hypersensitivity and anaemia are common complications in cases of severe flea infestation.



Fig. 9: *Nosopsyllus fasciatus* 100x

### Lice

Blood-sucking lice (*Polyplax spinulosa*) may be detected in large numbers, particularly in ageing, sick animals. They can cause pruritus, restlessness and anaemia. They may also transmit pathogenic agents (bacteria). Normally lice are host-specific and do not leave their host. Adults (Fig. 10) and eggs (nits) can be quite easily detected by careful examination of the fur.

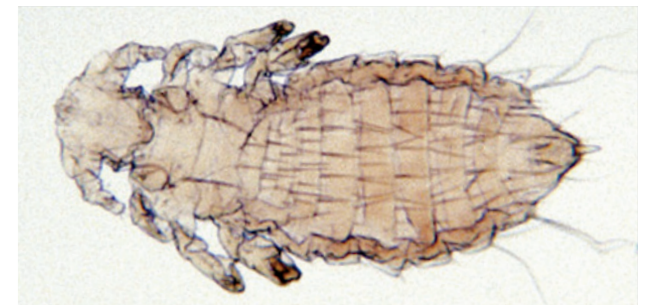

Fig. 10: *Polyplax spinulosa* 100x

### Mites

Fur-dwelling mites (*Myobia musculi*, *Myocoptes musculus*, *Radfordia affinis*, *Radfordia ensifera*) are pearly white mites seen near the base of the hair. These mites have a markedly characteristic body shape with the lateral margins extending between the limbs (Figs. 11 and 12). The eggs are cemented to the base of hairs. Transmission is by direct contact between rats (or other rodents such as mice). Clinical signs include pruritus, hair loss, erythema and thickening of the skin. Lesions are usually present around the head and shoulders. Secondary bacterial infections associated with self-trauma may occur. Skin scrapings, hair plucks or adhesive tape strips can be used to demonstrate the presence of fur-dwelling mites.




Fig. 11: *Myobia musculi* 400x



Fig. 12: *Myocoptes musculus* 400x

Burrowing mites such as *Notoedres muris* (Fig. 13) and *Trixacarus diversus* are responsible for mange. *Notoedres muris* prefers the epidermal tissue of the ears and face (Fig. 14). Wart-like, papular lesions appear, usually accompanied by yellow crusts. Skin scrapings are recommended to demonstrate the presence of these mites.

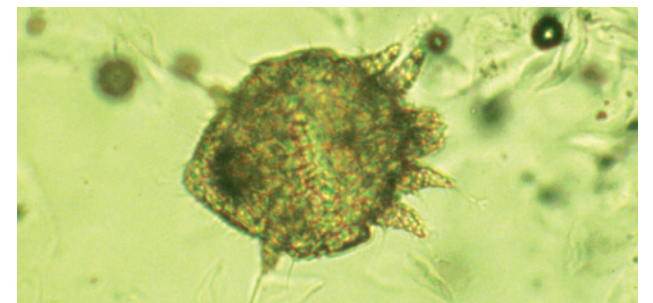


Fig. 13: *Notoedres muris*

The tropical rat mite (*Ornithonyssus bacoti*) is worldwide in distribution and primarily affects wild rodents such as rats and mice (Fig. 15). However, small, domestic mammals can also be possible reservoirs. The blood-feeding mites, which can cause skin irritation and anaemia, are active at night and seek dark hiding places during the daytime. A definitive diagnosis requires the detection of the parasite, which is more likely to be found in the environment (e.g. in cages, in litter and in corners or cracks of the living area) than on the host's skin itself. In the case of close human–pet contact, mites can occasionally cause pruritic dermatitis in humans.

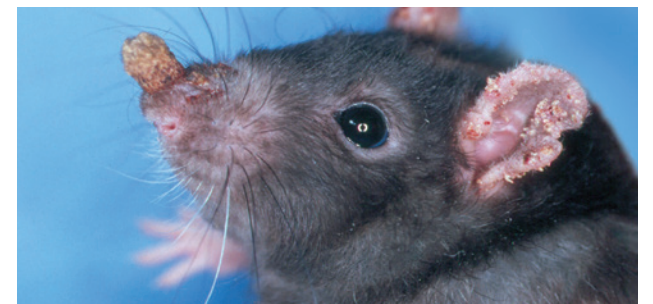


Fig. 14: *Notoedres muris* infection on a rat

### Ticks

Ixodid ticks can affect rats if they live outside. These ticks will feed for several days before they drop off naturally. They may be removed with a tick removal tool.



Fig. 15: *Ornithonyssus bacoti* 400x



## INTERNAL FUNGAL INFECTIONS

As with many mammals, *Encephalitozoon cuniculi* infection seldom occurs in rats.

*Pneumocystis* spp. are commensal inhabitants of the lungs of most rodents. These atypical fungal species are highly host-specific. *Pneumocystis carinii* and *P. wakefieldiae* are present in domestic rats. Secondary interstitial pneumonia may occur when the animals are immunosuppressed or debilitated owing to concurrent disease.

## EXTERNAL FUNGAL INFECTIONS

Rats can become infected by dermatophytes which belong to the complex species *Trichophyton mentagrophytes*. In most cases, rats remain asymptomatic but they may be a source of infection for other animals, including humans. When lesions are present, they usually include areas of circular or diffuse alopecia with scaling of the head, neck and tail (Fig. 16). Pruritus is absent. Diagnosis is made by microscopic demonstration of arthrospores in skin scrapings (KOH method) or by mycological cultures.

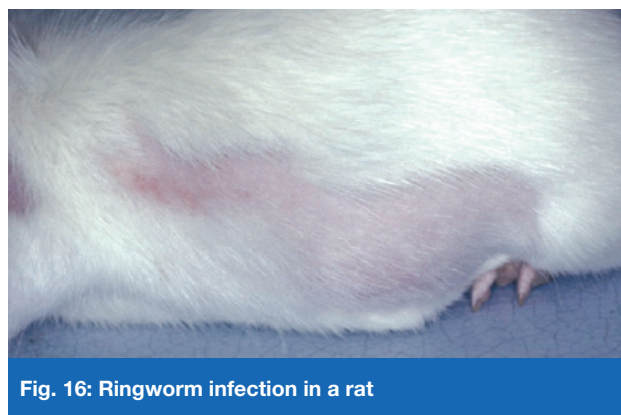

Fig. 16: Ringworm infection in a rat

## TREATMENT OF PARASITE AND FUNGAL INFECTIONS

When considering treatments for parasitic infections in rats, only a few suitable drugs are available and most are used off-label. In the case of topical application, the risk of toxicity is high due to the small size of the animals being treated and increased grooming activity which often accompanies pathological skin conditions.

### Roundworms

Ivermectin has been used to treat infections in rats caused by small intestinal worms and pinworms. Various dosage regimes for individual animals or those kept in groups have been recommended e.g. an oral dose at 0.2 mg/kg bodyweight daily for 5 consecutive days. Doramectin has also been effectively administered in the food at a rate of 0.2 mg/kg bodyweight daily for 4 days. Other anthelmintics such as fenbendazole and pyrantel have been shown to be effective against pinworms in various domestic animals. Oxantel (25 mg/kg bodyweight) or mebendazole (50 mg/kg bodyweight) administered twice are recommended for *T. muris* control. A combination spot-on containing imidacloprid 10% and moxidectin 1% as a single dose can also be effective.

### Tapeworms

Praziquantel (5–10 mg/kg bodyweight) orally or subcutaneously administered twice with an interval of 10 days is the most effective treatment for adult tapeworms in the intestine; an oral dosage of fenbendazole (20 mg/kg bodyweight) has also been used.

### Protozoa

Metronidazole (2.5 mg/ml of drinking water) and dimetridazole (1 mg/ml of drinking water) for 7–14 days have been recommended for many protozoal infections. Direct oral dosing with metronidazole is also possible with dosages of 10–40 mg/kg bodyweight every 24 hours. Coccidiosis can be treated with toltrazuril (10 mg/kg bodyweight orally using a 3 days on/3 days off schedule or at 25 ppm/l drinking water), sulfamerazine (1 mg/ml drinking water), sulfamethazine (1–5 mg/ml drinking water) or sulfaquinoxaline (1 mg/ml drinking water for 14–21 days).

### Fleas

Rats can be treated with an insecticide (fipronil 7.5 mg/kg bodyweight or imidacloprid 20 mg/kg bodyweight) topically every 30–60 days or an appropriate dose (15–30 mg/kg, repeated after 14 days) of selamectin poured onto the neck. It is also important to treat the environment.

### Lice

Ivermectin can be used at 0.2–0.4 mg/kg bodyweight subcutaneously or orally every 7–14 days for 3 treatments. The successful use of selamectin and fipronil (one drop applied topically onto the neck) and fipronil (applied as a spray over the whole body) has also been reported.

### Mites

Ivermectin can be administered subcutaneously or orally (0.2–0.4 mg/kg bodyweight) every 7–14 days for 2–3 treatments. Moxidectin (0.5 mg/kg bodyweight topically or 2 mg/kg bodyweight orally), doramectin (0.2–0.4 mg/kg bodyweight), selamectin, fipronil and permethrin have also been used orally, subcutaneously or topically. All affected and in-contact animals must be treated. For large groups of animals, ivermectin can be administered in the food. Interestingly, doramectin has been shown to have anxiolytic and anticonvulsant properties in rats. These properties may contribute to a reduction in grooming activity which may aid the resolution of cutaneous lesions.

### Ticks

Ticks can be eliminated with the application of fipronil (spray).

### Fungal Infections

Fenbendazole is recommended for the treatment of *Encephalitozoon cuniculi* infection and can assist in reducing the severity of the clinical signs, but has not been proven to eliminate infection.

As with rabbits, dermatophytes should be treated with a combination of systemic and topical treatments. Systemic treatment relies on daily oral administration of antifungal drugs: griseofulvin (25–50 mg/kg bodyweight – this can be given in two daily doses), itraconazole (2.5–10 mg/kg bodyweight) or terbinafine (10–30 mg/kg bodyweight). The decision to use topical therapy (with enilconazole or miconazole) should be based upon the owner's ability and willingness to pour or sponge the product over the entire coat of the infected animal. The frequency of topical treatment should be at least twice a week. When sponging or bathing, the owner needs to consider hypothermia and the animal should be dried carefully. Miconazole ointment can also be used on localised lesions but on a daily basis.

Hygiene measures are extremely important, especially treatment of the environment. For large groups of affected rodents, the environment can be sprayed with an enilconazole solution of 50 mg/m<sup>2</sup> twice weekly for 4 months. Additionally, the rat owner should use disposable gloves and thoroughly wash/disinfect clothes and shoes after every treatment and/or animal manipulation.

## PREVENTION OF PARASITE AND FUNGAL INFECTIONS

Prevention of parasite infection generally involves a combination of good environmental management and prophylactic drug treatments.

For example, quarantine should be initiated for animals of unknown history before mixing with resident animals and high standards of husbandry should be maintained with particular attention to feed and bedding. Dogs with access to areas frequented by rats should be regularly treated for tapeworms to avoid infecting the rats with tapeworm cysts.

Quarantine should be initiated for animals of unknown health history. Feed, cages and bedding should be kept clean and dogs and cats that have contact with rats should be regularly treated for parasites including fleas and tapeworms.

### Disclaimer:

Every effort has been taken to ensure that the information in the guideline, which is based on the authors' experience, is accurate. However the authors and publishers take no responsibility for any consequence arising from the misinterpretation of the information herein nor is any condition or warranty implied. ESCCAP emphasises that national, regional and local regulations must be borne in mind at all times before following ESCCAP advice. All dosages and indications are provided for guidance. However, vets should consult individual data sheets for details of locally approved treatment regimens.



### 3: Mice

Common or important parasites and fungal infections

CHAPTER 3:  
COMMON OR IMPORTANT PARASITES  
AND FUNGAL INFECTIONS OF MICE

PARASITES	INTERNAL	
	Roundworms	<i>Nematospiroides dubius</i> , <i>Nippostrongylus</i> spp., <i>Trichostrongylus</i> spp., <i>Syphacia obvelata</i> , <i>Aspiculuris tetraptera</i> , <i>Trichuris muris</i>
	Adult Tapeworms	<i>Rodentolepis nana</i> (syn. <i>Hymenolepis nana</i> ), <i>Hymenolepis diminuta</i> , <i>Cataenotaenia pusilla</i>
	Tapeworm Larvae	Alveolar hydatid cysts ( <i>Echinococcus multilocularis</i> ), larval stage of <i>Taenia taeniaeformis</i> (cysticercus fasciolaris)
	Protozoa	<i>Giardia</i> spp., <i>Chilomastix</i> spp., <i>Trichomonas muris</i> , <i>Spironucleus muris</i> (syn. <i>Hexamita muris</i> ), <i>Entamoeba muris</i> , <i>Eimeria</i> spp., <i>Cryptosporidium</i> spp., <i>Klossiella muris</i> , <i>Sarcocystis</i> spp., <i>Toxoplasma gondii</i>
	EXTERNAL	
	Fleas	<i>Leptospylla segnis</i> , <i>Ctenocephalides</i> spp.
	Lice	<i>Polyplax serrata</i>
	Mites	<i>Myobia musculi</i> , <i>Radfordia affinis</i> , <i>Myocoptes musculus</i> , <i>Psorergates</i> spp., <i>Liponyssoides sanguineus</i> , <i>Ornithonyssus bacoti</i>
	Ticks	<i>Ixodes</i> spp. and other Ixodidae
FUNGAL INFECTIONS	INTERNAL	
	Systemic	<i>Pneumocystis murina</i>
	EXTERNAL	
	Dermatophytes	<i>Trichophyton</i> spp.

INTERNAL PARASITES

**Roundworms**  
Pinworms (*Syphacia obvelata*, *Aspiculuris tetraptera*) are normally considered to be non-pathogenic nematodes that feed on bacteria inhabiting the intestinal tract of mice. They can, however, cause rectal, anal and perianal irritation, rectal prolapse and decreased weight gain. Debilitated animals are more susceptible to infection. Diagnosis is by coproscopy or the adhesive tape method. Eggs are typically flattened along one side.

*Trichuris muris* is a nematode of the large intestine, commonly known as whipworm. It is mostly associated with wild rats and mice but can also be found in domestic equivalents. Clinical signs can include mucoid diarrhoea with blood staining. Eggs can be isolated by centrifugal/flotation techniques. They are barrel or lemon-shaped, light brown in colour and show bipolar plugs.

**Tapeworms**  
The small tapeworms (*Rodentolepis nana*, *Hymenolepis diminuta*) may be found in the lumen of the small intestine of many mammalian hosts, including mice. Transmission of these parasites can be directly via ingestion of eggs, or indirectly through the ingestion of an intermediate host. Auto-infection is also possible as the eggs are capable of maturing within the intestinal lumen without leaving the host. Eggs which are present in the environment are also infective to humans. Strict hygiene and precautionary measures are needed e.g. cleaning and sterilisation to reduce the risk of transmission. Tapeworm infections are not normally clinically significant but weight loss, diarrhoea and death have been reported in heavily infected young mice. Diagnosis is made by faecal examination and the demonstration of thick-walled, round eggs containing an embryo with typical hooklets.

Mice are the intermediate hosts for *Taenia taeniaeformis*, an important tapeworm of cats. The larval stage (cysticercus fasciolaris) develops in the liver of mice but infections are usually asymptomatic. It has been suggested that liver neoplasia may be associated with this infection in mice. Mice with access to the external environment may also act as intermediate hosts of the fox and dog tapeworm *Echinococcus multilocularis*, an important zoonosis, but the larval infection (alveolar hydatid cysts) in mice represents no risk to humans.



## Protozoa

Flagellates of the genus *Giardia* are common intestinal parasites of rodents; mice are usually infected with *Giardia muris*. Infections are often subclinical but can result in diarrhoea and weight loss. Trophozoites attach to the mucous membrane of the intestinal villi and *Giardia* cysts (8–10 µm) can be detected in faecal samples.

*Spironucleus (Hexamita) muris* is a small piriform flagellate (2–3 x 7–9 µm) which inhabits the middle to lower part of the small intestine in mice. Infection has been associated with clinical signs such as weight loss and diarrhoea but only in certain strains of laboratory mice.

The coccidia of the genus *Eimeria* are often considered to be either non-pathogenic or secondary pathogens in rodents. Several host-specific species have been described in mice. *Eimeria pragensis* develops within the crypts of the caecum and colon and may be more pathogenic than the others. Clinical signs include profuse and often bloody diarrhoea, weight loss and death. Diagnosis of coccidiosis is by faecal examination (typical oocysts are detected) or by post-mortem examination showing enteric thickening and petechial haemorrhage.

Cryptosporidiosis occurs in a very large variety of rodent hosts. PCR-based genotyping and subtyping tools have allowed the identification of several *Cryptosporidium* species (including *C. parvum*, *C. muris*, *C. andersoni* and *C. wrairi*) and nearly 20 genotypes of uncertain species status in rodents worldwide. These organisms are found within the epithelial cells of the stomach or the intestines and it is possible for mixed infections with *Cryptosporidium* species/genotypes to occur. Cryptosporidiosis is often non-pathogenic in mice, although clinical signs associated with villous atrophy and enteritis may lead to weight loss, unthriftiness and death. Due to the small size of *Cryptosporidium* oocysts (approximately 4–5 µm), modified acid-fast staining of fresh faecal samples is needed to aid detection by microscopy.

Infection with the renal coccidian parasite *Klossiella spp.* has been reported in mice although this is often as an incidental finding. Whilst infections are usually asymptomatic, heavy parasite burdens can result in focal tubular necrosis. Diagnosis of klossiellosis is based on histopathology or the detection of sporocysts in the urine.

Mice are natural intermediate hosts of *Toxoplasma gondii* and acquire the infection via the ingestion of sporulated oocysts from cats or through vertical transmission via the placenta during pregnancy. The pathogenicity of the infection depends on the number and virulence of the infecting organisms; infections are usually asymptomatic, but can cause granulomatous inflammation in a wide variety of organs. Infected mice do not represent a direct risk for pet owners.

## EXTERNAL PARASITES

Ectoparasites are frequently reported in mice.

### Fleas

The ‘blind’ mouse flea (*Leptopsylla segnis*) may be observed in wild mice whereas fleas of the genus *Ctenocephalides* are often found infesting pet mice within the same household as cats and/or dogs. Flea infestation is associated with a dull coat, alopecia and pruritus. Secondary bacterial infection, hypersensitivity and anaemia are common complications in cases of severe infestation.

### Lice

Sucking lice (*Polyplax serrata*) are rarely observed in mice. When present, they can cause irritation and anaemia. *Polyplax serrata* also carries the rickettsial agent *Eperythrozoon coccoides* which causes murine eperythrozoonosis. Lice are host-specific and do not normally leave their host. Adults and eggs (nits) can be quite easily detected by careful examination of the fur.

## Mites

Fur-dwelling mites (*Myobia musculi*, *Radfordia affinis*, *Myocoptes musculus*) are pearly white mites seen near the base of the hair. The genera *Myobia* and *Radfordia* have a markedly characteristic body shape with the lateral margins extending between the limbs (Fig. 11). *Myocoptes* mites display heavily chitinated legs which are adapted for clasping (Fig. 12). The eggs are cemented to the base of hair. Transmission occurs by direct contact between mice (or other rodents for non-host-specific mites). A healthy mouse can tolerate a heavy infestation without apparent clinical signs. The increase in numbers and the occurrence of cutaneous lesions are usually associated with age or stress factors including pregnancy. Clinical signs include pruritus, hair loss, erythema and thickening of the skin. Secondary bacterial infection associated with self-trauma may occur. Skin scrapings, hair plucks or adhesive tape strips are recommended to demonstrate the presence of fur-dwelling mites.

Follicle-dwelling mites (*Psorergates spp.*) are small and spherical. Infestation is usually asymptomatic but sometimes small, white nodules may appear on ear pinnae and the rest of the body.

Infestation with the house mouse mite (*Liponyssoides sanguineus*) is usually asymptomatic unless large numbers of mites are present. These haematophagous mites may be detected on the animals but also in the environment. The house mouse mite may transmit *Rickettsia akari* (the agent responsible for rickettsial pox) to humans.

The tropical rat mite (*Ornithonyssus bacoti*) is worldwide in distribution and primarily affects wild rodents such as rats and mice (Fig. 15). However, small, domestic mammals can also be possible reservoirs. The blood-feeding mites, which can cause skin irritation and anaemia, are active at night and seek dark hiding places during the daytime. A definitive diagnosis requires the detection of the parasite, which is more likely to be found in the environment (e.g. in cages, in litter and in corners or cracks of the living area) than on the host’s skin itself. In the case of close human–pet contact, mites can occasionally cause pruritic dermatitis in humans.

### Ticks

Ixodid ticks can affect mice if they live outside. These ticks will feed for several days before they drop off naturally. They may be removed with a tick removal tool.

## INTERNAL FUNGAL INFECTIONS

*Pneumocystis spp.* are commensal inhabitants of the lungs of most rodents. These atypical fungal species are highly host-specific such as the mouse-adapted *Pneumocystis murina*. Secondary interstitial pneumonia may occur if an animal is immunosuppressed or debilitated.

## EXTERNAL FUNGAL INFECTIONS

Mice are usually infected by dermatophytes which belong to the complex species *Trichophyton mentagrophytes* and, in most cases, the infection is asymptomatic. However, transmission to other animals including humans may still occur. Lesions, when present, usually include areas of circular or diffuse alopecia with scaling on the head, neck and tail. Pruritus is absent. In the case of infection by *Trichophyton quinckeanum*, cup-shaped crusts may be seen grouped in patches or “favus”. Diagnosis is made by microscopic determination of arthrospores in skin scrapings (KOH method) or mycological cultures.

## TREATMENT OF PARASITE AND FUNGAL INFECTIONS

Few treatment options are available for parasitic infections in mice and most of these are used off-label. In the case of topical application, the risk of toxicity is high due to the very small size of the animals and increased grooming activity associated with pathological skin conditions.

### Roundworms

Ivermectin eliminates pinworms (with the same protocols as those recommended below for mites). Fenbendazole 20–50 mg/kg bodyweight orally for 5 days or 0.3% through the feed for 14 days may also be used. In all cases, it is imperative that disinfection of the environment occurs concurrently. Oxantel (25 mg/kg bodyweight) or mebendazole (50 mg/kg bodyweight) administered twice are recommended for *T. muris* control. A combination spot-on containing imidacloprid 10% and moxidectin 1% as a single dose can also be effective.

### Tapeworms

Praziquantel (30 mg/kg bodyweight twice or three times orally or subcutaneously at 10–14 day intervals) may be used. Treatment should be accompanied by husbandry changes to prevent reinfection.

### Protozoa

Metronidazole (2.5 mg/ml of drinking water for 5 days), dimetridazole (1 mg/ml drinking water) and ronidazole have been recommended for the treatment of *Giardia* spp. and *Spironucleus muris* infections. Hygienic measures are important for control of giardiasis. Coccidiosis can be treated with toltrazuril (10 mg/kg bodyweight orally using a 3 days on/3 days off schedule or at 25 ppm/l drinking water), sulfamerazine (1 mg/ml drinking water), sulfamethazine (1–5 mg/ml drinking water) or sulfaquinoxaline (1 mg/ml drinking water).

### Fleas

Mice can be treated topically with an insecticide such as fipronil 7.5 mg/kg bodyweight every 30–60 days (spray the pump into a gloved hand and spread on to the rodent avoiding the mouth, ears and eyes) or imidacloprid (20 mg/kg bodyweight). Alternatively, selamectin can be used (15–30 mg/kg bodyweight topically). It is also important to treat the environment.

### Lice

Ivermectin can be administered subcutaneously or orally (0.2–0.4 mg/kg bodyweight) every 7–14 days for 2–3 treatments.

### Mites

Several protocols have been tested, but in colonies eradication is always much more difficult to achieve than in individual animals. For mite-infected mice, the ‘micro-dot’ dermal delivery technique with undiluted ivermectin can be used. Two treatments (5 µL of 1% ivermectin solution) on the skin between the scapulae may be recommended at 10-day intervals. For large groups of mice, the total dose may be calculated based on group bodyweight and the ivermectin solution can be sprayed on the group and the cages. One part 1% ivermectin (10 mg/ml) should be mixed with 10 parts tap water and sprayed once weekly for three weeks. Please note that ivermectin is poorly soluble in water therefore using a lipid carrier such as propylene glycol is recommended. No more than 1 ml should be administered for each animal. For large groups of animals, ivermectin can be administered in the food. In mice, moxidectin (0.5 mg/kg bodyweight topically or 2 mg/kg bodyweight orally), selamectin (15–30 mg/kg bodyweight) and fipronil may also be used.

Mite infections can also be markedly reduced by dusting adult and weanling mice and their bedding with permethrin powder at weekly intervals. Cotton wool balls containing permethrin have also been used as bedding and nesting material to treat mice with mite infections.

### Ticks

Fipronil 7.5 mg/kg bodyweight every 30–60 days can be used for both prophylaxis and/or therapy (spray the pump into a gloved hand and spread on to the rodent avoiding the mouth, ears and eyes).

### Fungal Infections

A combination of systemic and topical treatment should be recommended. Systemic treatment relies on oral antifungal drugs: griseofulvin (25–50 mg/kg bodyweight daily – this can be given in two daily doses), itraconazole (2.5–10 mg/kg bodyweight daily) or terbinafine (10–30 mg/kg bodyweight daily). The decision to use topical therapy (with enilconazole or miconazole) should be based upon the owner’s ability and willingness to pour or sponge the product over the entire coat of the infected animal. The frequency of topical treatment should be at least twice a week. When sponging or bathing, the owner needs to consider hypothermia and the animal should be dried carefully. Miconazole ointment or cream can also be used on localised lesions but on a daily basis.

Hygiene measures are extremely important, especially treatment of the environment. For large groups of affected rodents, the environment can be sprayed with an enilconazole solution of 50 mg/m<sup>2</sup> twice weekly for 4 months. Additionally, the mouse owner should use disposable gloves and thoroughly wash/disinfect clothes and shoes after every treatment and/or animal manipulation.

## PREVENTION OF PARASITE AND FUNGAL INFECTIONS

Prevention of parasite infection generally involves a combination of good environmental management and prophylactic drug treatments.

For example, quarantine should be initiated for animals of unknown history before mixing with resident animals and high standards of husbandry should be maintained with particular attention to feed and bedding. Dogs with access to areas frequented by mice should be regularly treated for tapeworms to avoid infecting the mice with tapeworm cysts.

Quarantine should be initiated for animals with an unknown health history. Feed, cages and bedding should be kept clean and cats and dogs that have contact with rats or mice should be regularly treated for tapeworms.

Caesarean section followed by cross-fostering onto mite-free dams has been proposed as a means of eliminating mite infestation from commercial mouse colonies.

### Disclaimer:

*Every effort has been taken to ensure that the information in the guideline, which is based on the authors’ experience, is accurate. However the authors and publishers take no responsibility for any consequence arising from the misinterpretation of the information herein nor is any condition or warranty implied. ESCCAP emphasises that national, regional and local regulations must be borne in mind at all times before following ESCCAP advice. All dosages and indications are provided for guidance. However, vets should consult individual data sheets for details of locally approved treatment regimens.*



## 4: Gerbils

Common or important parasites and fungal infections



CHAPTER 4:  
COMMON OR IMPORTANT PARASITES  
AND FUNGAL INFECTIONS OF GERBILS

PARASITES	INTERNAL	
	Roundworms	<i>Dentostomella translucida</i> , <i>Syphacia</i> spp., <i>Aspicularis tetraptera</i>
	Adult Tapeworms	<i>Rodentolepis nana</i> (syn. <i>Hymenolepis nana</i> ), <i>Hymenolepis diminuta</i>
	Tapeworm Larvae	Larval stage of <i>Taenia taeniaeformis</i> (cysticercus fasciolaris)
	Protozoa	<i>Entamoeba muris</i> , <i>Tritrichomonas caviae</i> , <i>Giardia</i> spp., <i>Eimeria</i> spp., <i>Toxoplasma gondii</i>
	EXTERNAL	
	Mites	<i>Demodex</i> spp., <i>Liponyssoides sanguineus</i> , <i>Notoedres muris</i> , <i>Trixacarus diversus</i> , <i>Tyrophagus castellanii</i> , <i>Ornithonyssus bacoti</i>
FUNGAL INFECTIONS	EXTERNAL	
	Dermatophytes	<i>Trichophyton mentagrophytes</i> (complex species), <i>Microsporum gypseum</i>

INTERNAL PARASITES

Roundworms

*Dentostomella translucida* is the most common cause of pinworm infection in gerbils. The male pinworm is about 10 mm long and the female 20 mm. Transmission occurs by the ingestion of embryonated eggs which originate from around the perianal region and contaminate food and drinking water. Retrograde infections by penetration of liberated larvae from the perianal region back into the colon or caecum can also occur. The eggs are typical for oxyurid helminths, flattened along one side. Infected animals may show few or no clinical signs, however in heavy infections, gerbils may lose weight or show poor growth rates. Occasionally, these pinworms have been known to cause intestinal obstruction and intussusception.

*Syphacia muris*, *S. obvelata* and *Aspicularis tetraptera* are other oxyurid worms seen in gerbils. The latter two are most likely transmitted through contact with infected mice in the immediate environment.

Tapeworms

*Rodentolepis nana* and *Hymenolepis diminuta* are common small intestinal tapeworms of rodents. Infection may be transmitted directly via eggs (*R. nana*) or through ingestion of an arthropod intermediate host such as a flea or grain beetle. The clinical consequences of infection for the host are negligible. Diagnosis is made by faecal examination demonstrating the thick-walled round eggs containing a larva, typical hooklets and polar filaments. Note that the eggs of *R. nana* are infectious to humans, especially children.

The larval stage of the tapeworm *Taenia taeniaeformis* (cysticercus fasciolaris) is found in the liver of rodent intermediate hosts. The definitive host is the cat and occasionally the fox. Gerbils infected with these cysticerci do not seem to display any clinical signs.

Protozoa

*Entamoeba muris* is regularly observed in gerbils through the detection of cysts during coprological examinations. This species of *Entamoeba* appears to be non-pathogenic.

*Tritrichomonas caviae* may be observed in fresh faecal samples as motile protozoa with flagellae. *Tritrichomonas caviae* is not considered as a pathogen.

## EXTERNAL PARASITES

External parasites are uncommon in gerbils unless, for example, there are fleas such as *Ctenocephalides* spp. affecting dogs, cats or rabbits in the same household.

### Mites

Direct contact between animals or with infected skin matter (e.g. crusts from infected animals) may be an important route of infection with *Demodex* spp. At first, the clinical signs may resemble bite wounds. Dry hair, alopecia, crust formation and erythema of the skin with occasional ulceration can be caused by *Demodex* in immunosuppressed, young or elderly animals. Diagnosis is made by skin scrapings treated with KOH and examined microscopically.

The mite *Liponyssoides sanguineus* does not cause irritation unless present in large numbers.

*Trixacarus diversus* is a sarcoptic mite which can occasionally cause mange in gerbils. There is a higher risk of infection in breeding colonies than in animals kept individually. This mite can also be transmitted to humans causing lesions.

*Notoedres muris* is the other burrowing mite that can be found in gerbils causing irritation, pruritus and thickened skin. This mite may also cause lesions in humans.

In the case of *Tyrophagus castellani* (copra itch mite), handling of contaminated faeces by humans may cause itchy skin.

The tropical rat mite (*Ornithonyssus bacoti*) is worldwide in distribution and primarily affects wild rodents such as rats and mice (Fig. 15). However, small, domestic mammals including gerbils can also be possible reservoirs. The blood-feeding mites, which can cause skin irritation and anaemia, are active at night and seek dark hiding places during the daytime. A definitive diagnosis requires the detection of the parasite, which is more likely to be found in the environment (e.g. in cages, in litter and in corners or cracks of the living area) than on the host's skin itself. In the case of close human–pet contact, mites can occasionally cause pruritic dermatitis in humans.

## EXTERNAL FUNGAL INFECTIONS

In gerbils, most dermatomycoses are caused by *Microsporum* species, especially *M. gypseum*. Infections with *Trichophyton* species have also been described and of these, *T. mentagrophytes* (complex species) is the most commonly found in gerbils. Most animals do not show clinical signs but some individuals can develop circular areas of alopecia with erythema and crust formation particularly around the eyes, ears and nose. The skin can also appear dry and thickened. Infection may spread within a group and very young, stressed or immunosuppressed gerbils are the most susceptible. Diagnosis is made by detection via microscopy of arthrospores in skin scrapings (with KOH) or mycological cultures. Dermatophyte infections of animals are a major cause of zoonotic infection in humans.

## TREATMENT OF PARASITE AND FUNGAL INFECTIONS

There are very few treatments available to control parasitic infections in gerbils. Many of these are used off-label. Due to the small body size of gerbils and increased grooming activity associated with pathological skin conditions, there is a high risk of ingestion and toxicity when using topical treatments.

### Roundworms

Ivermectin eliminates pinworms with the same protocols as those recommended for mites (see below). Fenbendazole (20 mg/kg bodyweight orally for 5 days) may also be used. The product is generally administered in a week on/week off rotation for at least 3 cycles. In all cases, it is imperative that disinfection of the environment occurs concurrently.

### Tapeworms

Praziquantel (5–30 mg/kg bodyweight) administered subcutaneously or orally (three times at 14 day intervals) may be used. Treatment should be accompanied by husbandry changes to prevent reinfection (by *R. nana* which does not necessarily need intermediate hosts for transmission).

### Protozoa

Metronidazole (25 mg/kg bodyweight orally for 5 days) and fenbendazole (20–50 mg/kg bodyweight orally) have been recommended for *Giardia* control. Coccidiosis can be treated with toltrazuril (10 mg/kg bodyweight using a 3 days on/3 days off schedule or 25 ppm/l in drinking water) sulfamerazine (0.8–1 mg/ml drinking water), sulfamethazine (0.8 mg/ml in drinking water) or sulfaquinoxaline (1 mg/ml in drinking water).

### Mites

Eradication in colonies is always much more difficult to achieve than in individual animals. For mite-infected gerbils, the ‘micro-dot’ dermal delivery technique with undiluted ivermectin can be used. Two treatments (5 µL of a 1% solution of ivermectin) on the skin between the scapulae have been recommended at 10 day intervals. For large groups of gerbils, the total dose may be calculated based on group bodyweight and the ivermectin solution can be sprayed onto the group and the cages. One part 1% ivermectin (10 mg/ml) should be mixed with 10 parts tap water and sprayed once weekly for three weeks. Please note that ivermectin is poorly soluble in water therefore using a lipid carrier such as propylene glycol is recommended. No more than 1 ml (of diluted solution) should be administered for each animal. For large groups of animals, ivermectin can be administered in the food. *Demodex* infection should be continued for 3 weeks after there is evidence of healing or until 2 negative skin scrapings have been obtained. Amitraz (1.4 ml of a 5% solution/l) applied topically with a cotton wool ball at one to two week intervals has also proved effective in the treatment of *Demodex* infection in gerbils.

Mite infections can be reduced markedly by dusting adult and weanling gerbils and their bedding with permethrin powder at weekly intervals.

### Fungal Infections

A combination of systemic and topical treatment should be recommended for the treatment of dermatophytes. Systemic treatment relies on daily, oral antifungal drugs: griseofulvin (25–50 mg/kg bodyweight – this can be given in two daily doses), itraconazole (2.5–10 mg/kg bodyweight) or terbinafine (10–30 mg/kg bodyweight). The decision to use topical therapy (with enilconazole 0.2% or miconazole) should be based upon the owner's ability and willingness to pour or sponge the product over the entire coat of the infected animal. The frequency of topical treatment should be at least twice a week. When sponging or bathing, the owner needs to consider hypothermia and the animal should be dried carefully. Miconazole ointment or cream can also be used on localised lesions but on a daily basis.

Hygiene measures are extremely important, especially treatment of the environment. For large groups of affected rodents, the environment can be sprayed with an enilconazole solution of 50 mg/m<sup>2</sup> twice weekly for 4 months. Additionally, the gerbil owner should use disposable gloves and thoroughly wash/disinfect clothes and shoes after every treatment and/or animal manipulation.

## PREVENTION OF PARASITE AND FUNGAL INFECTIONS

Prevention of parasite infection generally involves a combination of good environmental management and prophylactic drug treatments.

For example, quarantine should be initiated for animals of unknown history before mixing with resident animals and high standards of husbandry should be maintained with particular attention to feed and bedding. Dogs with access to areas frequented by gerbils should be regularly treated for tapeworms to avoid infecting the gerbils with tapeworm cysts.

Any animals with an unknown health history should be quarantined to avoid the introduction of infections into a resident population. High hygiene standards in and around gerbil enclosures should be maintained and dogs and cats kept in the immediate area should be regularly treated for tapeworms

### **Disclaimer:**

*Every effort has been taken to ensure that the information in the guideline, which is based on the authors' experience, is accurate. However the authors and publishers take no responsibility for any consequence arising from the misinterpretation of the information herein nor is any condition or warranty implied. ESCCAP emphasises that national, regional and local regulations must be borne in mind at all times before following ESCCAP advice. All dosages and indications are provided for guidance. However, vets should consult individual data sheets for details of locally approved treatment regimens.*



## 5: Guinea Pigs

Common or important parasites and fungal infections



CHAPTER 5:  
COMMON OR IMPORTANT PARASITES  
AND FUNGAL INFECTIONS OF GUINEA PIGS

PARASITES	INTERNAL	
	Roundworms	<i>Paraspidodera uncinata</i>
	Adult Tapeworms	<i>Rodentolepis nana</i> (syn. <i>Hymenolepis nana</i> ), <i>Hymenolepis diminuta</i>
	Protozoa	<i>Entamoeba caviae</i> , <i>Tetratrichomonas</i> spp., <i>Tritrichomonas caviae</i> , <i>Chilomastix</i> spp., <i>Retortamonas</i> spp., <i>Giardia</i> spp., <i>Balantidium caviae</i> , <i>Cyathodium</i> spp., <i>Cryptosporidium</i> spp., <i>Eimeria caviae</i> , <i>Toxoplasma gondii</i> , <i>Sarcocystis</i> spp., <i>Klossiella</i> spp.
	EXTERNAL	
	Fleas	<i>Nosopsyllus fasciatus</i> , <i>Pulex irritans</i> , <i>Ctenocephalides</i> spp., <i>Rhopalopsylla clavicola</i>
	Lice	<i>Gliricola porcelli</i> , <i>Gyropus ovalis</i> , <i>Trimenopon hispidum</i>
	Mites	<i>Chirodiscoides caviae</i> , <i>Trixacarus caviae</i> , <i>Ornithonyssus bacoti</i> , <i>Demodex caviae</i>
	Ticks	<i>Ixodes</i> spp. and other Ixodidae
FUNGAL INFECTIONS	EXTERNAL	
	Dermatophytes	<i>Trichophyton mentagrophytes</i> (complex species)

INTERNAL PARASITES

Roundworms

*Paraspidodera uncinata*, commonly referred to as the guinea pig ‘pinworm’ is not a true oxyurid worm since it does not have the typical pinworm morphology. Instead it has a pre-cloacal sucker typical of the ascaridoid nematode *Heterakis*. Infection is more common in guinea pigs kept outside and is rarely found in caged animals. It resides in the caecum and colon. The male worm is 11 mm and the female 16 mm long. The eggs can be demonstrated using a faecal centrifugation/flotation technique. Infection of the host occurs after ingestion of the embryonated egg. *Paraspidodera uncinata* is considered to be non-pathogenic.

Tapeworms

*Rodentolepis nana* (syn. *Hymenolepis nana*) is a cestode found in the small intestine of rodents. It measures 20–40 mm in length and has a unique life cycle. Typically, the life cycle includes an invertebrate intermediate host (fleas, beetles) with cysticercoid larvae that can be ingested by the guinea pig (definitive host). Alternatively, eggs shed in the faeces may be ingested directly by the guinea pig and lead to completion of the life cycle. Eggs in the environment may also infect humans, especially children. Normally the infection does not cause clinical signs in the guinea pig, but significant infections in young animals may result in poor growth, intestinal impaction and occasionally death. Diagnosis is confirmed by faecal examination and the detection of thick-walled, round eggs (40–45 x 34–37 µm) each containing a typical six-hooked larva (hexacanth embryo).

Infections with *Hymenolepis diminuta* are less common and result in less serious consequences than infections with *R. nana*. Diagnosis is made through faecal examination, the eggs being similar but larger than those of *R. nana* (60–88 x 52–81 µm).

## Protozoa

Common protozoa which occur in the large intestine include *Entamoeba caviae*, *Tetratrichomonas* spp., *Tritrichomonas caviae*, *Chilomastix* spp. and *Retortamonas* spp. These parasites are considered non-pathogenic.

*Giardia* spp. are flagellate protozoa commonly found in the small intestine. Trophozoites measure 12 x 5 µm and are attached to the mucous membrane of the intestinal villi. *Giardia* cysts can measure 8–10 µm. Both trophozoites and cysts can be identified in the faeces of infected guinea pigs using the centrifugation/flotation technique with zinc sulphate. Depending on the parasite load, the host may lose weight. *Giardia* spp. vary in pathogenicity, most being of little clinical significance but infection may cause diarrhoea in young animals.

Guinea pigs are considered to be the only rodent species capable of harbouring enteric ciliates. *Balantidium caviae* is found in the caecum, often in large numbers. It is an oval organism measuring 50–120 x 45–80 µm and contains a macro and a micronucleus. The resistant stage is a large dark-coloured, thick-walled cyst measuring 40–60 µm in diameter. Although parasites may be present in large numbers, there are no reports of clinical disease caused by this protozoan. *Cyathodinium* spp. are also common parasites of the caecum in guinea pigs. They are cone-shaped anteriorly and taper towards the distal end. There are no reports of clinical disease associated with this parasite.

*Cryptosporidium* spp. are parasites of the small intestine, particularly the jejunum and ileum, in a wide variety of hosts. The oocysts of this parasite are very small (7 x 5 µm) with smooth walls. Several techniques are used to diagnose cryptosporidiosis. One of the more common methods is the Ziehl Neelsen staining of faecal smears (which demonstrates the red-coloured oocysts).

*Cryptosporidium wrairi* is a specific parasite of guinea pigs and may cause enteritis, diarrhoea and death. Information about the possibility of *C. parvum* cross-infection between these rodents and other animals is limited but it is considered possible that this parasite can induce disease in other hosts e.g. ruminants and humans.

*Eimeria caviae* is the only species of *Eimeria* to be found in guinea pigs. The smooth and oval oocysts measuring 13–26 x 12–23 µm can be isolated from the faeces. Developing stages are found in the colon and occasionally in the caecum. In serious infections, macroscopic lesions, which can be seen through the serosal wall as white or yellow plaques, may occur together with small haemorrhagic lesions. In young animals coccidiosis often occurs, especially with overcrowding and poor hygiene, resulting in high infection rates and occasional death.

*Toxoplasma gondii* can also be found in guinea pigs. They can be infected by oocysts in food and drinking water contaminated with cat faeces or through vertical transmission via the placenta during pregnancy. Infections can prove fatal in guinea pigs. Infected individuals may abort and cysts have been observed in muscle, brain, conjunctiva and the inner ear causing respiratory distress, fever and neurological signs. Diagnosis usually depends on post-mortem findings. Contact with infected guinea pigs poses no risk to humans.

It is likely that guinea pigs can be infected by several species of *Sarcocystis*. Whilst there is no documented clinical information on this parasite, other rodents are known to act as intermediate hosts and harbour *Sarcocystis* cysts of different sizes in muscle tissue. At post-mortem, thick-walled cysts may be identified through histopathological examination of muscle.

The coccidian parasites *Klossiella cobayae* and *K. caviae* have large ellipsoidal, double-walled oocysts some of which contain round sporocysts each with 3–10 sporozoites. Both species are host-specific to guinea pigs and they target the endothelial cells of kidney tubules. *Klossiella cobayae* may cause a mild nephritis in guinea pigs.

## EXTERNAL PARASITES

Guinea pigs, like rabbits, are prone to external parasite and fungal infections.

### Fleas

Fleas are uncommon in guinea pigs unless there are fleas affecting other pets such as dogs, cats and rabbits in the same household.

### Lice

There are three species of chewing lice which infect guinea pigs, namely *Gliricola porcelli*, *Gyropus ovalis* and *Trimenopon hispidum*. Louse eggs may be visible to the naked eye on the coat (Fig. 17).

The most common is *Gliricola porcelli*, the “slender” guinea pig louse (Fig. 18). Females measure 1.68 x 0.27 mm and the male slightly less. Eggs are cemented to the base of the hair shaft, particularly to the fine hair around the back legs and anus.

*Gyropus ovalis* is another common guinea pig louse. It is fractionally shorter but broader than *Gliricola*. Females are slightly larger than the males and measure 1.03 x 0.52 mm. The head is wide with projecting margins giving it a robust appearance.

*Trimenopon hispidum* is the largest, but least common, guinea pig louse. Females measure 1.72 x 0.68 mm and males 1.6 x 0.64 mm. They are dark brown and produce eggs with a distinctive surface pattern which differentiates them from the previous two species.

All three parasites feed on epidermal scales and occasionally on sebaceous secretions (*G. porcelli*). Transmission occurs by direct contact between host animals. Heavy infestations are associated with pruritus, alopecia and flaky skin lesions around the neck and ears. These lice can usually be seen on the fur, especially with a magnifying glass and they can be identified by microscopic examination of the hair and skin scrapings.

### Mites

The fur-dwelling mite *Chirodiscoides caviae* is a parasite specific to the guinea pig. It is a small mite roughly twice as long as it is broad. The female measures 460–500 µm in length and the male is slightly smaller. The first two pairs of legs are highly chitinized, long and well-adapted for wrapping around the hair (Fig. 19). *Chirodiscoides caviae* produce long slender eggs which are attached to the middle region of the hair shafts usually on hairs in the gluteal region, flank and trunk. Widespread infestation occurs more often in sick or immune-deficient animals with other underlying disease. Scratching, self-excoriations, erythema, alopecia, and scaling may be associated with heavy infestations. This can lead to self-trauma and ulcerative dermatitis which usually begins on the head. The animal's coat will typically have a rough appearance. Anorexia may result, possibly due to hair accumulation in the mouth.

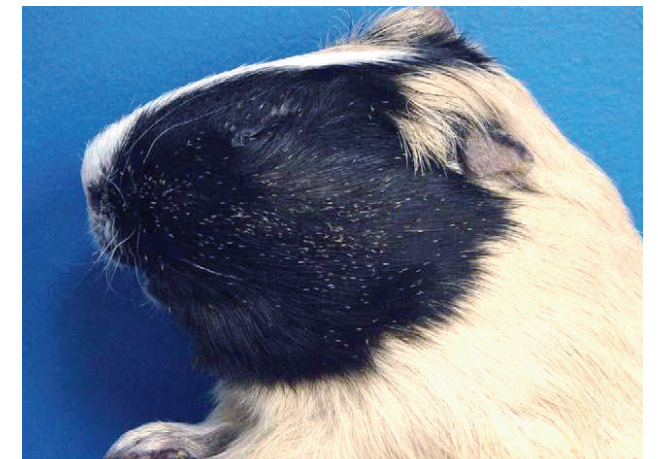

Fig. 17: Guinea pig with louse eggs or nits visible on dark hairs

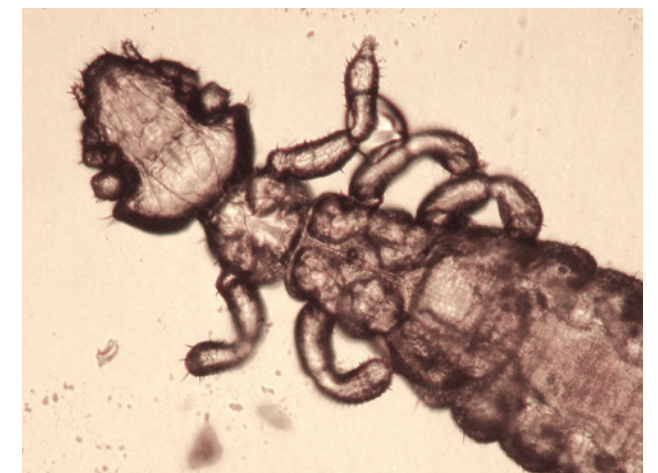

Fig. 18: *Gliricola porcelli* 100x



Fig. 19: *Chirodiscoides caviae* 400x



*Trixacarus caviae* is a species-specific sarcoptid mite which occasionally causes mange in individuals but is more common in breeding colonies. Mites are usually found in pockets or burrows in the epidermis. The cuticle is striated and grooved with small, wedge-shaped scales (Fig. 20). The eggs are laid in tunnels. Burrows are difficult to detect and just a few mites can cause considerable irritation, pruritus and lesions similar to canine sarcoptic mange. *Trixacarus caviae* is smaller than *S. scabiei*; females measure 160-230 µm long and 120-180 µm wide. Males measure 120-150 µm long and 85-100 µm wide. Both are white and round with fine striations anteriorly.

Irritation and scratching leads to thickened, wrinkled skin and hair loss. Lesions can become secondarily infected if treatment is not started immediately. The most commonly affected areas are the neck and shoulder region and the lower abdomen and thighs (Fig. 21). Mite infections may be subclinical but signs can appear if the animal becomes immunosuppressed during transportation or in pregnancy. In some cases, animals can experience seizure-like episodes after intensive scratching which is usually indicative of a heavy *T. caviae* infestation. This mite is easily transmitted through direct animal-to-animal contact e.g. sows feeding their young or through contact with contaminated hutches or bedding. *Trixacarus caviae* can also be transmitted to humans who have had close contact with infested animals and pruritic skin lesions on the hands, arms and neck have been observed in children.

*Demodex caviae* is host-specific and is found in the hair follicles. Infestations are usually asymptomatic although immunodeficiency due to inadequate housing conditions, stress and/or qualitative or quantitative malnutrition supports the proliferation of these parasites. Infestations with *D. caviae* can lead to alopecia, erythema, papules and crust formation. Lesions are most commonly seen on the head, forelegs, and trunk. Mild pruritus may be present. *Demodex caviae* has a typical cigar-shaped body, with females being larger than males. The tropical rat mite (*Ornithonyssus bacoti*) is worldwide in distribution and primarily affects wild rodents such as rats and mice (Fig. 15). However, small, domestic mammals including guinea pigs can also be possible reservoirs. The blood-feeding mites, which can cause skin irritation and anaemia, are active at night and seek dark hiding places during the daytime. A definitive diagnosis requires the detection of the parasite, which is more likely to be found in the environment (e.g. in cages, in litter and in corners or cracks of the living area) than on the host's skin itself. In the case of close human-pet contact, mites can occasionally cause pruritic dermatitis in humans.

#### Ticks

Ixodid ticks can affect guinea pigs if they live outside. These ticks will feed for several days before they drop off naturally. They may be removed with a tick removal tool.

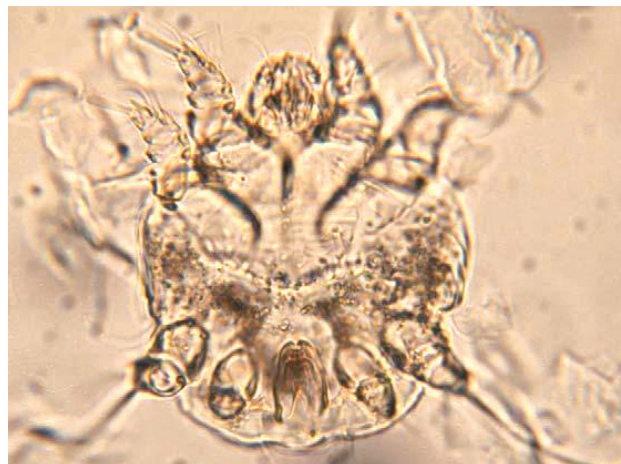

Fig. 20: *Trixacarus caviae* 400x

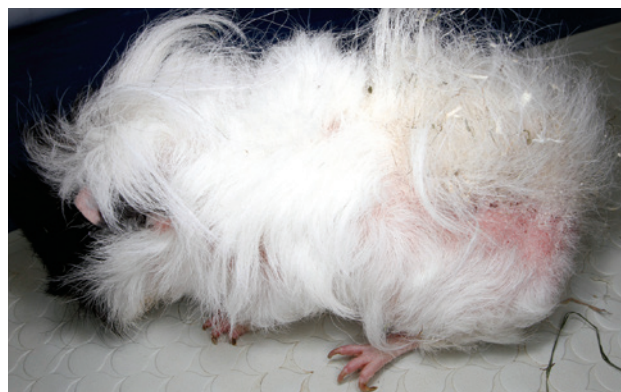

Fig. 21: Lesions caused by *Trixacarus caviae*

## EXTERNAL FUNGAL INFECTIONS

If dermatophytosis is diagnosed in guinea pigs, a dermatophyte belonging to the complex species *Trichophyton mentagrophytes* is the causative agent in the majority of cases (Fig. 22). *Trichophyton benhamiae* var. *lutea* is now regularly reported. This variety has an appearance in culture similar to *Microsporum canis*. Transmission occurs through direct contact between animals or via a contaminated environment. Young animals are especially sensitive and are more likely to show clinical signs. Lesions begin as broken hairs and circular, scaly alopecia at the tip of the nose, spreading to the periocular area, forehead and ears (Fig. 23). In serious cases, the sacrolumbar area is affected. Pruritus is minimal or absent. Some animals may show erythema, papules, pustules and crusts. Diagnosis is made by microscopic demonstration of arthrospores in skin scrapings (KOH method) or mycological cultures. This agent can be isolated in clinically normal guinea pigs and is considered to be an important zoonosis.

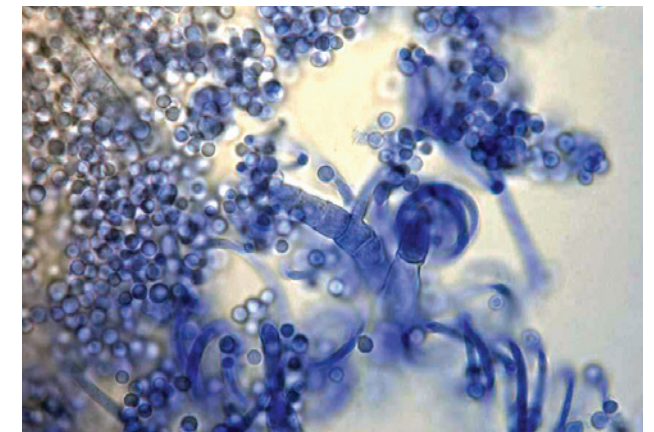


Fig. 22: Microscopic appearance of *Trichophyton mentagrophytes* (complex species) 1000x

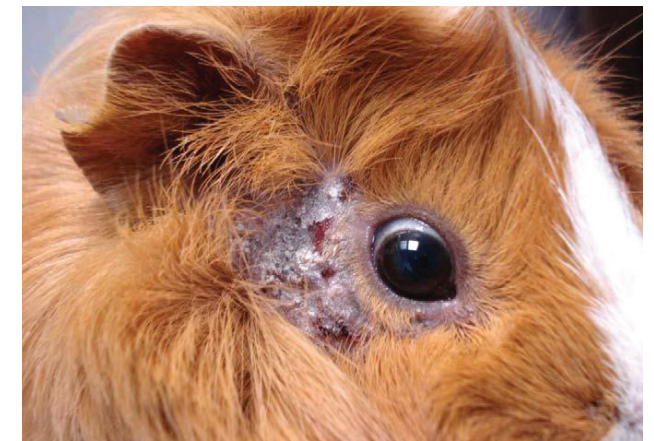

Fig. 23: Ringworm infection in a guinea pig

## TREATMENT OF PARASITE AND FUNGAL INFECTIONS

There are only a few treatments available for parasitic infections in guinea pigs and all of them are used off-label. In the case of topical application, the risk of toxicity is high because of the very small size of the animals and due to the increased grooming activity associated with pathological skin conditions.

#### Roundworms

Macrocyclic lactones are effective and ivermectin (with the same protocols as those recommended for mites) should eliminate pinworms. Fenbendazole (20–50 mg/kg bodyweight orally) may also be used and is generally administered in a week on/week off rotation for at least 3 cycles. Alternatively, levamisole 25 mg/kg bodyweight subcutaneously (or 10 mg/kg bodyweight orally) can be administered. In all cases, it is imperative that disinfection of the environment occurs concurrently.

#### Tapeworms

Praziquantel administered subcutaneously at 5–10 mg/kg bodyweight (twice with an interval of 10 days) may be used. Treatment should be accompanied by husbandry changes to prevent reinfection.



### Protozoa

Treatment twice daily for 5 days with fenbendazole (20–50 mg/kg bodyweight, orally) or metronidazole (25 mg/kg bodyweight twice daily, orally for 5–7 days) has been recommended for the treatment of giardiasis in guinea pigs. Coccidiosis can be treated with toltrazuril (10 mg/kg bodyweight orally using a 3 day on/3 day off schedule) or with sulfamerazine (1 mg/ml in drinking water), sulfamethazine (1–5 mg/ml in drinking water) or sulfaquinoxaline (1 mg/ml in drinking water) or sulfadiazine + trimethoprim (30 mg/kg bodyweight every 12 hours in the feed).

Infections with *Tritrichomonas caviae*, *Entamoeba caviae* and *Balantidium coli* can be treated with metronidazole (25 mg/kg bodyweight orally) every 12 hours for 7 days.

In all cases, appropriate hygienic measures should accompany therapeutic treatments.

### Fleas

Topical application of imidacloprid (20 mg/kg bodyweight) or selamectin (20–30 mg/kg bodyweight) is effective in treating flea infestations in guinea pigs.

### Lice

Topical application of imidacloprid, permethrin or lactones such as ivermectin, doramectin (0.2–0.4 mg/kg bodyweight) and selamectin are effective in treating louse infestations in guinea pigs. Usually treatments have to be repeated after 7–10 days.

### Mites

Eradication is always much more difficult to achieve within colonies than in individual animals. For mite-infected guinea pigs, the ‘micro-dot’ dermal delivery technique with undiluted ivermectin can be used. Two treatments (5 µL of a 1% solution) applied to the skin between the scapulae at 10 day intervals is recommended. Selamectin spot-on applied directly to the skin has also been used and found effective at a single dose of 5–15 mg/kg. For large groups of guinea pigs, the total dose may be calculated based on group bodyweight and the ivermectin solution can be sprayed on the group and on the cages. One part 1% ivermectin (10 mg/ml) should be mixed to 10 parts tap water and sprayed once weekly for three weeks. Please note that ivermectin is poorly soluble in water therefore using a lipid carrier such as propylene glycol is recommended. No more than 1 ml (of the diluted solution) should be administered for each animal. As in mice, moxidectin and selamectin may also be used.

Fipronil spray (7.5 mg/kg bodyweight) has also been used topically by applying the spray to gloved hands and then carefully rubbing it into the animal’s hair coat avoiding the mouth, ears and eyes). This is done twice with an interval of 10 days between applications.

Amitraz (0.3% solution topically applied to the affected areas and repeated weekly or a 0.025% solution applied over the whole body twice a week over 3 weeks) works against *Sarcoptes*. Permethrin + imidacloprid (10 + 50 mg/kg bodyweight) and washing the whole body with a shampoo containing deltamethrin have also been used in the treatment of mite infections in guinea pigs.

*Trixacarus caviae* can be treated with ivermectin injected subcutaneously (0.2–0.4 mg/kg bodyweight repeated every 7–14 days) or by topical application of imidacloprid/moxidectin (0.05–0.1 ml/animal of a 10% + 1% spot-on solution), imidacloprid/permethrin (0.1 ml/kg of a 10% + 50 % spot-on solution) or doramectin (0.4 mg/kg bodyweight).

Seizure-like behaviour, which sometimes accompanies *Trixacarus* infection, can be controlled with diazepam.

### Fungal Infections

A combination of systemic and topical treatments should be recommended for the treatment of dermatophytes. Systemic treatment relies on daily, oral antifungal drugs: griseofulvin (60–80 mg/kg bodyweight – this can be given in two daily doses), itraconazole (2.5–20 mg/kg bodyweight), fluconazole (2.5–20 mg/kg bodyweight) or terbinafine (8–40 mg/kg bodyweight). The decision to use topical therapy (with enilconazole 0.2% or miconazole) should be based upon the owner’s ability and willingness to pour or sponge the product over the entire coat of the infected animal. The frequency of topical treatment should be at least twice a week. When sponging or bathing, the owner needs to consider hypothermia and the animal should be dried carefully. Miconazole ointment or cream can also be used on localised lesions but on a daily basis.

Ringworm is transmitted very easily by fungal spores on grooming equipment. If ringworm is suspected, shared grooming equipment should be avoided. The spores can persist in hutches and the surrounding environment for years, therefore thorough disinfection is essential after an outbreak to kill the fungus. Gloves should be worn when cleaning the environment and bedding should be burned.

Hygiene measures are extremely important, especially treatment of the environment. For large groups of affected rodents, the environment can be sprayed with an enilconazole solution of 50 mg/m<sup>2</sup> twice weekly for 4 months. Additionally, the guinea pig owner should use disposable gloves and thoroughly wash/disinfect clothes and shoes after every treatment and/or animal manipulation.

## PREVENTION OF PARASITE AND FUNGAL INFECTIONS

Prevention of parasite infection generally involves a combination of good environmental management and prophylactic drug treatments.

For example, quarantine should be initiated for animals of unknown history before mixing with resident animals and high standards of husbandry should be maintained with particular attention to feed and bedding. Dogs with access to areas grazed by guinea pigs should be regularly treated for tapeworms to avoid infecting the guinea pigs with tapeworm cysts.

Quarantine measures should be put in place for all animals of unknown health history joining a resident individual or group and high standards of hygiene should be maintained, especially in relation to food and bedding.

### Disclaimer:

*Every effort has been taken to ensure that the information in the guideline, which is based on the authors’ experience, is accurate. However the authors and publishers take no responsibility for any consequence arising from the misinterpretation of the information herein nor is any condition or warranty implied. ESCCAP emphasises that national, regional and local regulations must be borne in mind at all times before following ESCCAP advice. All dosages and indications are provided for guidance. However, vets should consult individual data sheets for details of locally approved treatment regimens.*



## 6: Hamsters

Common or important parasites and fungal infections

CHAPTER 6:  
COMMON OR IMPORTANT PARASITES  
AND FUNGAL INFECTIONS OF HAMSTERS

PARASITES	INTERNAL	
	Roundworms	<i>Syphacia</i> spp., <i>Aspiculuris tetraptera</i> , <i>Dentostomella translucida</i>
	Adult Tapeworms	<i>Rodentolepis nana</i> (syn. <i>Hymenolepis nana</i> ), <i>Hymenolepis diminuta</i>
	Tapeworm Larvae	Larval stage of <i>Taenia taeniaeformis</i> (cysticercus fasciolaris)
	Protozoa	<i>Giardia</i> spp., <i>Spironucleus muris</i> , <i>Entamoeba</i> spp., <i>Hexamastix</i> spp., <i>Trichomonas</i> spp., <i>Tritrichomonas</i> spp., <i>Tetratrichomonas</i> spp., <i>Cryptosporidium muris</i> , <i>Toxoplasma gondii</i>
	EXTERNAL	
	Fleas	<i>Nosopsyllus fasciatus</i> , <i>Ctenocephalides felis</i>
FUNGAL INFECTIONS	Mites	<i>Demodex</i> spp., <i>Notoedres</i> spp., <i>Sarcoptes scabiei</i> , <i>Trixacarus diversus</i> , <i>Ornithonyssus bacoti</i> , <i>Myobia musculi</i> , <i>Myocoptes musculus</i> , <i>Spleorodens clethrionomys</i>
	EXTERNAL	
	Dermatophytes	<i>Trichophyton mentagrophytes</i> (complex species), <i>Microsporum</i> spp.

INTERNAL PARASITES

Roundworms

*Syphacia* spp. are among the most common helminths in rodents. In hamsters, the most prevalent species are *Syphacia criceti* and *S. mesocriceti* although infections with *S. obvelata* and *S. muris*, more commonly found in mice and rats, have also been reported. These nematodes can infect animals kept both inside and outside and can be difficult to eradicate. All stages of these worms reside in the large intestine (caecum and colon). The hamster oxyurid, *S. mesocriceti*, is a small colourless worm with a striated cuticle. Males measure 1.2–1.5 mm long and females 5–7 mm long. *Syphacia mesocriceti* has reduced lips around a triangular stoma, a distinguishing feature from the rat and mouse pinworms. The oesophagus is typical of oxyurids: club-shaped with a prominent bulb. Another feature is the presence of lateral extensions of the cuticle around the anterior region.

These nematodes have a direct life cycle. Female *Syphacia* migrate to the rectum and anus to deposit their eggs around the perineum. These eggs are operculated, thin-walled, flattened along one side and measure 100–140 x 30–40 µm. Transmission occurs by the ingestion of embryonated eggs either directly via faecal/oral contact or from a contaminated environment. Eggs are released in the faeces, usually in response to the activity of the host, and can survive for weeks in the environment. Other rodents may also be a source of *S. obvelata* and *S. muris* infection.

Generally, *Syphacia* spp. infection in hamsters, particularly immunocompetent animals, has little clinical effect. In some cases anal/perineal pruritus, rectal prolapse, poor coat (especially in the perianal zone) and weight loss have been observed, although these animals may have had other concurrent infections. *Syphacia* infection can be diagnosed using a perianal tape test, faecal flotation/centrifugation or by detection of adult worms in the faeces or in the caecum at post-mortem.

The nematode *Aspiculuris tetraptera* which commonly infects mice is known to occasionally infect domestic hamsters. They are found in the caecum with the female and male worms measuring 2.6–4.7 x 0.19–0.25 mm and 2.3–3.2 x 0.15–0.17 mm respectively. Like *Syphacia* spp., they have three lips around the mouth, although the presence of cervical alae gives the head an arrow-like appearance. In both sexes the tail is blunt and conical in shape.

*Dentostomella translucida* from the Mongolian gerbil (*Meriones unguiculatus*) is another oxyurid that can occasionally infect hamsters. These nematodes are longer than those previously discussed (female length: 9.6–13 mm, male: 6–13 mm) and are found in the small, rather than the large, intestine.



## Tapeworms

*Rodentolepis nana* is considered to be the most significant endoparasite in hamsters. This tapeworm, which measures 20–40 mm long, is unique in the sense that it can alternate between a typical indirect and a direct life cycle. The typical cycle requires an invertebrate intermediate host (flea, beetle). Hamsters act as the definitive host and become infected by ingesting invertebrates which contain the cysticercoid larvae. It is also possible for hamsters to become infected directly if eggs released in the faeces are ingested. This is more likely to occur if sanitary measures are poor and/or the animal ingests its own faeces; auto-infection is quite likely given that hamsters have coprophagic behaviour. Eggs released into the environment are also infective to humans, especially children. *Rodentolepis nana* infections tend to be asymptomatic in the hamster but heavy infections, particularly in young animals, can cause enteritis, poor growth, intestinal impaction and, in rare cases, death. A pot-bellied syndrome may be observed in weanlings but this is usually associated with heavy infections of *R. nana* in conjunction with heavy infections of protozoa such as *Spironucleus muris* and *Giardia* spp. Poor housing conditions and overcrowding may also contribute to the onset of disease. Diagnosis is based on the detection of thick-walled, round eggs (40–45 x 34–37 µm) containing a typical six-hooked larva (hexacanth embryo).

Infections caused by *Hymenolepis diminuta* are less common than those caused by *R. nana*. Hamsters can only acquire this tapeworm by ingesting the cysticercoid larval stages found in flea and beetle intermediate hosts. *H. diminuta* is often found in the proximal small intestine. Adult stages have an unarmed scolex and produce less severe clinical signs than *R. nana*. Diagnosis is achieved via the detection of eggs (60–88 x 52–81 µm) during faecal examination.

The larval stage (cysticercus fasciolaris) of the cat tapeworm *Taenia taeniaeformis* can also be found in hamsters. The adult stage is an intestinal parasite of cats and other related carnivores. Hamsters become infected after ingesting eggs passed in the faeces of the definitive host and a strobilocercus larval stage develops in the liver. This can be seen macroscopically as a creamy white body lying coiled in the cyst beneath the capsule of the liver on post-mortem examination. The number of specimens ranges from 1 up to 20 and they may produce no clinical signs, although there are reports of possible carcinogenic effects of this parasite.

## Protozoa

*Giardia* spp. are flagellate protozoa commonly found in the small intestine. *Giardia muris* in hamsters is morphologically indistinguishable from similar organisms found in mice. Both trophozoites and cysts can be found in faeces and hamsters are infected after ingestion of cysts. Trophozoites measure 12 x 5 µm, are pear-shaped and attached to the mucous membrane of the intestinal villi. *Giardia* cysts can measure 8–10 µm. Generally, infection with *Giardia* in hamsters is asymptomatic but diarrhoea may occur in aged individuals with concomitant amyloidosis. Depending on the parasite load, the host may lose weight. Due to the potential for transmission of this parasite between different host species, owners with mice should minimise contact with hamsters.

The protozoan *Spironucleus muris* primarily infects mice, but can also infect golden hamsters. The life cycle is direct and infection occurs via the ingestion of cysts. Following excystation, the released trophozoites colonise the crypts of Lieberkuhn, primarily in the ileum and caecum. Whilst *Spironucleus* has been reported as an incidental finding, infection may affect the host's immune system and cause a desquamation of the intestinal epithelium, oedema, inflammation and cell death. Proliferative ileitis and acute enteritis have also been described. In most cases there are no clinical signs despite the pathologic changes in the intestinal tract.

*Hexamastix* spp., *Trichomonas* spp., *Tritrichomonas* spp. and *Tetratrichomonas* spp. are all flagellate protozoa which, together with *Entamoeba* spp., occur in the large intestine. They are considered to be non-pathogenic and clinical signs of disease are rare and usually restricted to weanlings. *Trichomonas muris*, *T. wenyoni*, *T. minuta* and a form resembling *T. microti* have been recorded in the golden hamster. Various parasitological tests can be performed to isolate intestinal protozoa including direct smear and cellophane tape tests.

*Cryptosporidium* spp. are parasites of the small intestine, particularly the jejunum and ileum, in a wide variety of hosts. The oocysts of this parasite are very small (7 x 5 µm) with smooth walls. Natural infections with *Cryptosporidium muris* have been reported in hamsters. Clinical signs may include diarrhoea due to proliferative ileitis. Diagnosis is by modified Ziehl Neelsen stain of faecal smears showing red coloured oocysts or by PCR. Sheather's sugar method will aid the concentration of oocysts. PCR is needed for speciation.

Hamsters may become infected either by ingesting oocysts of *Toxoplasma gondii* which can occur if food and drinking water is contaminated by cat faeces or by vertical transmission via the placenta during pregnancy. Infected hamsters represent no risk for pet owners.

## EXTERNAL PARASITES

### Fleas

Hamsters are susceptible to infestation by several flea species including *Nosopsyllus fasciatus* and *Ctenocephalides felis*. Fleas are not common in hamsters but they can become infected through contact with other animals such as pet dogs, cats or rabbits. The rat flea, *Nosopsyllus fasciatus*, may be of particular concern since it is recognised as an intermediate host for *Rodentolepis nana*.

### Mites

*Myocoptes musculinus* and *Myobia musculi* are stationary fur-dwelling mites which nourish from dandruff, superficial epithelial cells and lymph. They are pearly white mites seen near the base of the hair. These mites have a markedly characteristic body shape with the lateral margins extending between the limbs – *M. musculinus* having the third pair (males) and third and fourth pair of legs (females) modified for hair clasping (Figs. 11 and 12). The eggs are cemented to the base of hairs. Transmission is by direct contact between hamsters (or other rodents such as mice, which are considered as the main host). Clinical signs include pruritus, hair loss, erythema and thickening of the skin. Lesions are usually present around the head (including the basis of whiskers and lashes, laterally at the eyes, ears and ear ground) and shoulders. Secondary bacterial infections associated with self-trauma due to intensive pruritus may occur, also leading to restlessness or apathy and weight loss. Accumulation of mite faeces can appear in the neck like a brownish necklace. Skin scrapings, hair plucks or adhesive tape strips can be used to demonstrate the presence of fur-dwelling mites. In particular the ears and surrounding of the eyes should be examined.

*Notoedres muris* (hamster ear mite) and *Notoedres cati* (cat mange mite) can on rare occasions infest the hamster. These mites burrow into the skin of the ears, nose, feet, and perianal area. Infestation of hamsters with *Notoedres* spp. causes lesions similar to those described in mice. They may become severe and are observed on the ear pinnae, face, genitalia, tail and limbs. Clinical signs include severe pruritus, erythema, crust formation and hyperpigmentation.

*Sarcoptes scabiei* rarely infects hamsters. In infected animals, mites occur in pockets or burrows in the epidermis. Females measure 300–400 µm in length and the males around 250 µm. They can be identified by examination of the cuticle which is striated and grooved with small wedge-shaped scales. The eggs are laid in tunnels. Burrows are difficult to detect and the presence of only a few mites may cause considerable irritation, pruritus and lesions similar to canine sarcoptic mange. This mite is easily transmitted through direct contact with other animals including humans.

*Trixacarus diversus* is a sarcoptic mite which can occasionally cause mange in hamsters. There is a higher risk of infection in breeding colonies compared to individual animals. This mite can also be transmitted to humans causing lesions.

The three host-specific *Demodex* species *D. aurati*, *D. criceti* and *D. cricetuli* are the most common ectoparasites of hamsters. The dam seems to be a major source of infection for young hamsters. Male hamsters tend to have larger mite loads. Infestations with *D. aurati*, *D. criceti* and *D. cricetuli* rarely show clinical signs due to their low pathogenicity. *Demodex criceti*, a small, round mite, ranges from 87–103 µm in length (Fig. 24). It creates and lives in epidermal pits that extend to the stratum germinativum of the epidermis. *Demodex aurati*, a thin, elongated mite, approximately twice as long as *D. criceti*, infests the hair follicles at or above the sebaceous canal. Up to five mites may be found in a single hair follicle.

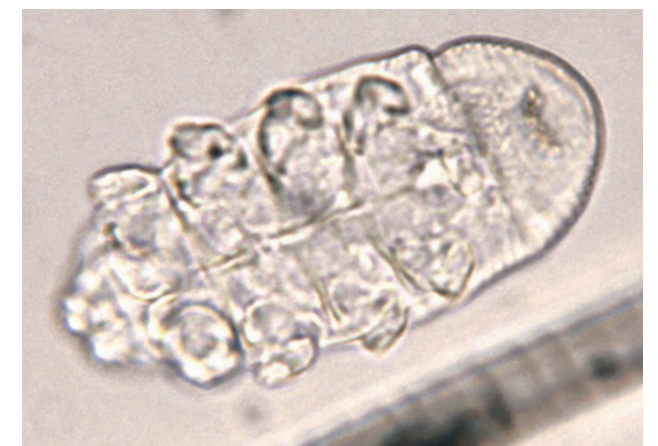

Fig. 24: *Demodex criceti*

Immunodeficiency, especially associated with Cushing's disease, supports proliferation of these parasites and this may be caused in part by inadequate housing conditions, stress and/or qualitative or quantitative malnutrition. Other stress factors that can lower resistance to disease include advanced age, concurrent infection with other agents and prolonged exposure to carcinogenic agents. Areas of alopecia that may develop are not pruritic and there is usually minimal inflammation of the skin. In serious cases, erythema, papules and crusts may also be present. Dry, scaly alopecia on the flanks and over the rump, back, neck and hindquarters are characteristic of demodicosis in aged hamsters.

Diagnosis of mite infections is confirmed by microscopic examination of plucked hairs or skin scrapings. These mites have a typical cigar shape, with females being larger than males.

A close relative of the Syrian hamster, the Armenian hamster (*Cricetulus migratorius*), has a specific mite, *Demodex cricetuli*, which closely resembles *D. aurati*. Adult males are approximately 173 µm in length and adult females are roughly 192 µm in length. Another species, *Demodex sinocricetuli*, may be observed in the striped hamster (*Cricetulus barabensis*) which is its natural host. Adult males measure approximately 112–128 µm in length and adult females approximately 127–150 µm. These two species are found in the hair follicles and they may induce lesions and clinical signs similar those seen in the Syrian or golden hamster.

The tropical rat mite (*Ornithonyssus bacoti*) is worldwide in distribution and primarily affects wild rodents such as rats and mice (Fig. 15). However, small, domestic mammals including hamsters can also be possible reservoirs. The blood-feeding mites, which can cause skin irritation and anaemia, are active at night and seek dark hiding places during the daytime. A definitive diagnosis requires the detection of the parasite, which is more likely to be found in the environment (e.g. in cages, in litter and in corners or cracks of the living area) than on the host's skin itself. In the case of close human–pet contact, mites can occasionally cause pruritic dermatitis in humans.

*Spleorodens clethrionomys* is a mite found in the nasal passages of the Syrian hamster. The adult mites range between 300–360 µm in length and are milky white and oval shaped. The preferred site for these mites is on the mucosa in the posterior parts of the nasal cavities. Pathogenic effects and clinical signs are unknown and infestation with *S. clethrionomys* is normally an incidental finding at necropsy.

## EXTERNAL FUNGAL INFECTIONS

Spontaneously occurring dermatophytosis is extremely rare in the Syrian hamster. There are a few reports of ringworm in hamsters due to *Trichophyton mentagrophytes* (complex species) or *Microsporum* spp. Infection may be unapparent or may be associated with dry, scaly skin and crust formation with broken hairs. Lesions begin as broken hairs and circular, scaly alopecia at the tip of the nose, spreading to the periocular areas, forehead and ears. In serious cases, the sacrolumbar area is often affected. Pruritus is minimal or absent. Some animals may exhibit erythema, papules, pustules and crusts. Transmission occurs through direct contact. Young animals in particular may demonstrate clinical signs. Ringworm is transmitted very easily by fungal spores on grooming equipment. If fungal infection is suspected, shared grooming equipment should be avoided. Diagnosis is confirmed by microscopic determination of arthrospores in skin scrapings (KOH method) and mycological cultures. These dermatophytes can be isolated in clinically normal hamsters and they can be an important source of zoonotic infection for humans.

## TREATMENT OF PARASITE AND FUNGAL INFECTIONS

There are only a few treatments available for parasitic infections in hamsters and all of these are used off-label. In the case of topical application, the risk of toxicity is high because of the very small size of the animals and due to the increased grooming activity associated with many pathological skin conditions.

### Roundworms

Ivermectin (with the same protocols as those recommended below for mites) eliminates pinworms. Fenbendazole may also be used at a dosage of 10 mg/kg bodyweight administered orally in a week on/week off rotation for at least 3 cycles or 20–50 mg/kg bodyweight for 5 consecutive days. In all cases, it is imperative that disinfection of the environment occurs concurrently. High standards of hygiene (appropriate cleaning and disinfection of enclosures) must be implemented to eliminate sources of infection. It is important to note that the eggs are resistant to desiccation and also some chemical cleaning products. *Aspicularis tetraptera* infection can be treated in a similar way to other oxyurid infections.

### Tapeworms

Praziquantel, orally at a dosage of 5–30 mg/kg bodyweight every 14 days or subcutaneously for 7 days may be used. Oral fenbendazole at 20–50 mg/kg bodyweight for 5 days is also recommended. Treatment should be accompanied by husbandry changes to prevent reinfection.

### Protozoa

Fenbendazole is indicated for the treatment of giardiasis in hamsters at a dosage of 20–50 mg/kg bodyweight orally once a day for 7–10 days. *Giardia* infection is more difficult to eradicate in hamsters than mice as treatment with metronidazole therapy (20–40 mg/kg bodyweight orally, twice daily, for 14 days) is more successful in the latter. Thorough cleaning and the elimination of all faecal matter in the environment is recommended, as well as the use of chlorine-based disinfectants or sterilisers.

In case of persistent clinical signs with *Spironucleus muris*, dimetridazole (1 mg/ml drinking water, for 14 days) and metronidazole (70 mg/kg bodyweight three times daily orally, for 14 days) can be used.

There are no specific studies on toxoplasmosis in hamsters, however, trimethoprim or sulfa preparations may be effective. Treatment with sulfadiazine (25 mg/kg bodyweight for 2–3 weeks) can be useful for cases of toxoplasmosis, as may treatment with the antibiotic enrofloxacin (5–10 mg/kg bodyweight orally for 5–10 days).

Coccidiosis can be treated with toltrazuril (10 mg/kg bodyweight for 3 days orally), trimethoprim sulfa (30 mg/kg bodyweight orally or subcutaneously, twice a day for 2–3 weeks), sulfamerazine (1 mg/ml in drinking water for 2–3 weeks), sulfamethazine (1–5 mg/ml in drinking water for 2–3 weeks) or sulfaquinoxaline (1 mg/ml in drinking water for 2–3 weeks).

### Fleas

Hamsters can be treated topically with an insecticide such as fipronil (7.5 mg/kg bodyweight which can be repeated every 30–60 days as a prophylactic measure - spray the pump into a gloved hand and spread on to the rodent avoiding the mouth, ears and eyes) or imidacloprid (20 mg/kg bodyweight). Alternatively, selamectin can be used (15–30 mg/kg bodyweight topically). It is also important to treat the environment.



## Mites

Several protocols have been tested, but in colonies, eradication is always much more difficult to achieve than in individual animals. For mite-infected hamsters, the ‘micro-dot’ dermal delivery technique with undiluted ivermectin can be used. Two treatments (5 µL of a 1% solution of ivermectin) on the skin between the scapulae may be recommended at 10 day intervals. For large groups of hamsters the total dose may be calculated based on group bodyweight and the ivermectin solution can be sprayed on the group and the cages. One part 1% ivermectin (10 mg/ml) should be mixed with 10 parts tap water and sprayed once weekly for three weeks. Please note that ivermectin is poorly soluble in water therefore using a lipid carrier such as propylene glycol is recommended. No more than 1 ml (of the diluted solution) should be administered for each animal. For large groups of animals, ivermectin can be administered in the food. In hamsters, moxidectin (0.4 mg/kg bodyweight), doramectin (0.2–0.4 mg/kg bodyweight) and selamectin (15–30 mg/kg bodyweight) may also be used.

Mite infections can be reduced markedly by dusting adult and weanling hamsters and their bedding with permethrin powder at weekly intervals.

Benzyl benzoate or amitraz (0.013% topical bath) can be applied topically to focal demodicosis and local lesions. Generalised demodicosis in hamsters can be treated with ivermectin (0.2–0.4 mg/kg bodyweight every 5–7 days) and selamectin (6–30 mg/kg bodyweight on the neck every 14 days).

Selamectin (15–30 mg/kg bodyweight or 1 drop behind the neck) is the preferred drug used to treat *Ornithonyssus bacoti* infestation. Alternatively, fipronil (2 pump sprays into a gloved hand spread on the rodent avoiding the mouth, ears and eyes) may be used, or (diluted) ivermectin (see above).

If mites are found at post mortem examination, all in-contact animals should be treated with a macrocyclic lactone accompanied by cleaning and disinfection of the environment with an acaricidal product.

## Fungal Infections

A combination of systemic and topical treatment should be recommended. Systemic treatment relies on daily oral antifungal drugs: griseofulvin (25–50 mg/kg bodyweight – this can be given in two daily doses), itraconazole (2.5–10 mg/kg bodyweight) or terbinafine (10–30 mg/kg bodyweight). The decision to use topical therapy (with enilconazole 0.2% or miconazole) should be based upon the owner’s ability and willingness to pour or sponge the product over the entire coat of the infected animal. The frequency of topical treatment should be at least twice a week. When sponging or bathing, the owner needs to consider hypothermia and the animal should be dried carefully. Miconazole ointments or creams can also be used on localised lesions but on a daily basis.

Hygiene measures are extremely important, especially treatment of the environment. For large groups of affected rodents, the environment can be sprayed with an enilconazole solution of 50 mg/m<sup>2</sup> twice weekly for 4 months. As the spores are able to last for years in the environment, thorough cleaning and disinfection is essential after an outbreak. For any of these procedures, gloves should be worn and bedding should be burned to prevent contamination with highly resistant spores. Additionally, the hamster owner should use disposable gloves and thoroughly wash/disinfect clothes and shoes after every treatment and/or animal manipulation.

## PREVENTION OF PARASITE AND FUNGAL INFECTIONS

Prevention of parasite infection generally involves a combination of good environmental management and prophylactic drug treatments.

For example, quarantine should be initiated for animals of unknown history before mixing with resident animals and high standards of husbandry should be maintained with particular attention to feed and bedding. Dogs with access to areas frequented by hamsters should be regularly treated for tapeworms to avoid infecting the hamsters with tapeworm cysts.

Quarantine measures should be put in place for all animals of unknown health history joining a resident individual or group. Feed and bedding should be kept clean and good standards of hygiene and sanitary measures should be maintained. These include thorough washing of the animal, cleaning and sterilisation of the cage and control of fleas and other insects which may act as parasite intermediate hosts. Interspecies transmission is an important issue that must be considered if owners have other rodent species in the same household.

The best control of the larval stage cysticercus fasciolaris of *Taenia taeniaeformis* in hamsters depends on adequate hygiene measures such as the regular removal of litter and the prevention of contamination of bedding or feed materials with cat faeces. Cats kept in the same household should be treated with an effective tapeworm treatment.

### Disclaimer:

*Every effort has been taken to ensure that the information in the guideline, which is based on the authors’ experience, is accurate. However the authors and publishers take no responsibility for any consequence arising from the misinterpretation of the information herein nor is any condition or warranty implied. ESCCAP emphasises that national, regional and local regulations must be borne in mind at all times before following ESCCAP advice. All dosages and indications are provided for guidance. However, vets should consult individual data sheets for details of locally approved treatment regimens.*





## 7: Chinchillas

Common or important parasites and fungal infections

CHAPTER 7:  
COMMON OR IMPORTANT PARASITES  
AND FUNGAL INFECTIONS OF CHINCHILLAS

PARASITES	INTERNAL	
	Roundworms	<i>Syphacia obvelata</i>
	Adult Tapeworms	<i>Rodentolepis nana</i> (syn. <i>Hymenolepis nana</i> )
	Tapeworm Larvae	Larval stages of several <i>Taenia</i> spp. and <i>Echinococcus multilocularis</i>
	Protozoa	<i>Giardia</i> spp., <i>Cryptosporidium</i> spp., <i>Eimeria chinchillae</i> , <i>Sarcocystis</i> spp., <i>Toxoplasma gondii</i>
	EXTERNAL	
	Fleas	<i>Ctenocephalides</i> spp.
	Lice	<i>Lagidiophthirus</i> spp.
	Mites	<i>Atricholaelaps chinchillae</i>
FUNGAL INFECTIONS	EXTERNAL	
	Dermatophytes	<i>Trichophyton mentagrophytes</i> (complex species), <i>Microsporum</i> spp.

INTERNAL PARASITES

Roundworms

The pinworm *Syphacia obvelata* is occasionally observed in the caecum and colon of chinchillas. The male is 1.6 mm long and the tail, which ends in a long threadlike appendage, has caudal alae. The female is 3.5–5.7 mm long and lays relatively large eggs (110–142 x 30–40 µm) which can be found using the adhesive tape method. Eggs are typically flattened along one side. Other than perianal irritation, infections tend to be asymptomatic.

Tapeworms

Infection with the tapeworm *Rodentolepis nana* (syn. *Hymenolepis nana*) is normally asymptomatic in chinchillas. *R. nana* may be acquired directly via the ingestion of eggs or through ingestion of an arthropod intermediate host such as a flea or grain beetle. Humans, particularly children, are also at risk of becoming infected with the eggs. Strict hygiene and precautionary measures such as cleaning and sterilisation may reduce the chance of transmission. Diagnosis of *R. nana* infection is made by faecal examination and the demonstration of thick-walled round eggs (50 x 40 µm) containing larvae with typical hooklets and polar filaments.

Chinchillas can sometimes become infected with cysticercus pisiformis, the larval stage of *Taenia pisiformis*. Lesions tend to occur in the subserosa of the liver, although this is often an incidental finding as infections are normally asymptomatic. Occasionally, alveolar hydatid cysts (*Echinococcus multilocularis*) can be found in the liver and larvae of *Taenia crassiceps* can cause subcutaneous or intraperitoneal cysticercosis. Both of the latter cestode infections can be lethal. Dogs, foxes and occasionally cats are the definitive hosts of these tapeworms.

### Protozoa

*Giardia* spp. are relatively common protozoal parasites of the small intestine. Trophozoites line the mucous membranes of intestinal villi and can interfere with the absorption of nutrients by the host. Clinical signs depend on the parasite load and include weight loss, lethargy, a hunched posture and a dull coat. Diarrhoea is seen most commonly in young animals. External stresses such as a change in diet or overcrowding may also play a part in the onset of disease. Diagnosis involves the detection of *Giardia* cysts (8–10 µm) in faecal samples. At present, it is unclear whether *Giardia* from chinchillas belongs to a zoonotic assemblage.

There is only one recorded case of diarrhoea in a young chinchilla (eight months of age) found to be shedding *Cryptosporidium*. There is no available information on the molecular typing of this parasite so it is unknown whether *C. parvum* or another species was present. It is therefore necessary to highlight the potential zoonotic nature of this type of infection. There is no formally recommended treatment for *Cryptosporidium*.

Coccidiosis caused by *Eimeria chinchillae* can occur, particularly in young chinchillas. It is thought to be a chronic infection which produces sporadic episodes of diarrhoea. Diagnosis is by the detection of oocysts in the faeces.

Rarely, *Sarcocystis* spp. have been associated with sudden death in young chinchillas and at post-mortem exam microscopic lesions have been identified in several organs.

The presence of *Toxoplasma gondii* in chinchillas may be either congenital or acquired. Food contaminated with cat faeces containing *Toxoplasma* oocysts is the main route of transmission. A wide range of clinical signs may be observed including respiratory problems, fever, lassitude and neurological signs such as incoordination, torticollis, convulsions and lameness. Toxoplasmosis can be associated with high mortality rates in chinchillas. Diagnosis is often based on pathological findings at post-mortem. Contact with infected chinchillas does not represent a health risk to humans.

## EXTERNAL PARASITES

Due to their dense coats, chinchillas tend to be relatively free from most ectoparasites. Infestation with fleas, ticks, or other fur-dwelling parasites is very rare and occurs mostly in wild chinchillas.

### Fleas

Fleas of the genus *Ctenocephalides* may be commonly observed in chinchillas that are in the same household as infested dogs and cats.

### Lice

Lice (*Lagidiophthirus* spp.) can cause irritation which may lead to scratching, rubbing and/or biting which damages the fur. In heavy infestations, scabs and crusts may form on the surface of the skin resembling mange. Wart-like structures may also be observed, especially on areas with little or no hair such as the ears. Normally, lice are host-specific and do not leave their hosts, transmission occurring by direct contact.

### Other Ectoparasites

Other ectoparasites (the mite *Atricholaelaps chinchillae* and booklice of the genus *Liposcelis*) may also be responsible for cutaneous lesions.

The tropical rat mite (*Ornithonyssus bacoti*) is worldwide in distribution and primarily affects wild rodents such as rats and mice (Fig. 15). However, small, domestic mammals including chinchillas can also be possible reservoirs. The blood-feeding mites, which can cause skin irritation and anaemia, are active at night and seek dark hiding places during the daytime. A definitive diagnosis requires the detection of the parasite, which is more likely to be found in the environment (e.g. in cages, in litter and in corners or cracks of the living area) than on the host's skin itself. In the case of close human–pet contact, mites can occasionally cause pruritic dermatitis in humans.

## EXTERNAL FUNGAL INFECTIONS

Chinchillas are frequently infected by the dermatophyte *Trichophyton mentagrophytes* (complex species) (Fig. 25).




Fig. 25: Ringworm due to *Trichophyton mentagrophytes* (complex species) infection in a chinchilla

## TREATMENT OF PARASITE AND FUNGAL INFECTIONS

Few treatments exist for parasitic infections in chinchillas and most of these are used off-label. The risk of toxicity when using topical preparations is high because of the very small size of the animals and the increased grooming activity seen in animals with skin pathologies.

### Roundworms

Ivermectin eliminates pinworms using the same protocols as those recommended for the treatment of mites (see below). Fenbendazole (20 mg/kg bodyweight orally daily for five days in the feed) may also be used. In all cases, it is imperative that disinfection of the environment occurs concurrently.

### Tapeworms

Praziquantel (in the feed at 6–10 mg/kg bodyweight and then repeated after 10 days) may be used. Treatment should be accompanied by improvements in husbandry to prevent reinfection.

### Protozoa

*Giardia* spp. infection can be treated with 25–50 mg/kg bodyweight fenbendazole at 12–24 hourly intervals for 2–5 days. Metronidazole should be used with caution in chinchillas.

Coccidiosis can be treated with toltrazuril (10 mg/kg bodyweight orally using a 3 days on/3 days off schedule or at 25 ppm/l drinking water), sulfamerazine (1 mg/ml drinking water for 10 days), sulfamethazine (1 mg/ml drinking water for 2–4 days twice with a 4 day interval) or sulfaquinoxaline (1 mg/ml drinking water for 2–3 weeks).

### Fleas

Spray applications of fipronil (1–2 pump sprays into a gloved hand spread on the animal avoiding the mouth, ears and eyes) or pyrethrins can be used to treat fleas. Topical selamectin (6–12 mg/kg bodyweight spot-on) or imidacloprid (10–20 mg/kg bodyweight spot-on) can also be used.

### Lice

Fipronil can be used to treat lice in chinchillas (1–2 pump sprays into a gloved hand spread on the animal avoiding the mouth, ears and eyes).

### Mites

Several protocols have been tested, but eradication is much more difficult to achieve in colonies than in individual animals. For mite-infected chinchillas, ivermectin at 0.2–0.4 mg/kg bodyweight orally or subcutaneously for 7–14 days, or imidacloprid at dosages up to 40 mg/kg bodyweight topically, may be administered.



### Fungal Infections

A combination of systemic and topical treatment should be recommended. Systemic treatment relies on oral antifungal drugs e.g. griseofulvin (25–50 mg/kg bodyweight – this can be given in two daily doses), itraconazole (2.5–10 mg/kg bodyweight daily) or terbinafine (10–30 mg/kg bodyweight daily). The decision to use topical therapy (with enilconazole or miconazole) should be based upon the owner's ability and willingness to pour or sponge the product over the entire coat of the infected animal. Other options for topical treatments include terbinafine spray which is highly effective and safe and non-alcoholic chlorhexidine solution at a concentration of less than 2%. The frequency of topical treatment should be at least twice a week and continued until an improvement is observed.

Ringworm is readily transmitted by fungal spores on grooming equipment or in bedding so grooming equipment should not be shared and hygiene measures such as environmental decontamination are also required. As ringworm is a zoonotic disease, gloves should be worn when cleaning the environment and bedding should be burned. For large groups of affected rodents, the environment can be sprayed with an enilconazole solution at a rate of 50 mg/m<sup>2</sup> twice weekly for 4 months. Additionally, the chinchilla owner should use disposable gloves and thoroughly wash/disinfect clothes and shoes after every treatment and/or animal manipulation.

### PREVENTION OF PARASITE AND FUNGAL INFECTIONS

Prevention of parasite infection generally involves a combination of good environmental management and prophylactic drug treatments.

For example, quarantine should be initiated for animals of unknown history before mixing with resident animals and high standards of husbandry should be maintained with particular attention to feed and bedding. Dogs with access to areas grazed by chinchillas should be regularly treated for tapeworms to avoid infecting the chinchillas with tapeworm cysts.

Quarantine should be initiated for animals of unknown health history joining an existing group of animals. Feed, hutches and bedding should be kept clean. Dogs and cats kept in the same environment should be regularly treated for tapeworms and fleas.

#### Disclaimer:

*Every effort has been taken to ensure that the information in the guideline, which is based on the authors' experience, is accurate. However the authors and publishers take no responsibility for any consequence arising from the misinterpretation of the information herein nor is any condition or warranty implied. ESCCAP emphasises that national, regional and local regulations must be borne in mind at all times before following ESCCAP advice. All dosages and indications are provided for guidance. However, vets should consult individual data sheets for details of locally approved treatment regimens.*



## 8: Ferrets

### Common or important parasites and fungal infections

CHAPTER 8:  
COMMON OR IMPORTANT PARASITES  
AND FUNGAL INFECTIONS OF FERRETS

PARASITES	INTERNAL	
	Roundworms	<i>Toxascaris leonina</i> , <i>Toxocara cati</i> , <i>Uncinaria criniformis</i> , <i>Capillaria</i> spp., <i>Ancylostoma</i> spp., <i>Filaroides</i> spp., <i>Dirofilaria immitis</i>
	Adult Tapeworms	<i>Taenia</i> spp., <i>Mesocoestoides</i> spp., <i>Ariotaenia procyonis</i> , <i>Dipylidium caninum</i>
	Protozoa	<i>Eimeria</i> spp., <i>Giardia</i> spp., <i>Spironucleus muris</i> (syn. <i>Hexamita muris</i> ), <i>Tritrichomonas</i> spp., <i>Toxoplasma gondii</i>
	EXTERNAL	
	Fleas	<i>Ctenocephalides</i> spp. and other flea species
	Lice	<i>Trichodectes</i> spp.
	Mites	<i>Sarcoptes scabiei</i> , <i>Otodectes cynotis</i> , <i>Ornithonyssus bacoti</i> , <i>Demodex</i> spp.
	Ticks	<i>Ixodes</i> spp. and other Ixodidae
	EXTERNAL	
FUNGAL INFECTIONS	Dermatophytes	<i>Microsporum canis</i> , <i>Trichophyton mentagrophytes</i> (complex species)

INTERNAL PARASITES

Roundworms

*Toxocara cati* is an important parasite for ferrets which can become infected when they ingest infective eggs from the environment. Ferrets can also become infected when they eat undercooked meat or prey on an infected paratenic host (e.g. rodents). Following acquisition, eggs hatch in the small intestine releasing larvae which undergo a hepato-tracheal migration, with the life cycle completed when the larvae are coughed up and swallowed, returning to the small intestine to complete their migration. Adult worms inhabit the small intestine where they lay eggs that are then passed in the faeces. *T. cati* has a prepatent period of approximately 8 weeks. The eggs can become infective after several weeks and may survive in the environment for years. More rarely, there have been reports of *Toxocara canis* infections in domestic ferrets.

Both *Toxocara* species and *Toxascaris leonina* can often be found in ferrets living together with cats and/or dogs, due to the opportunity of cross transmission. As with dogs and cats, *Toxocara* spp. in domestic ferrets can be transmitted to humans, and hygiene and sanitation measures should be implemented to prevent their consequences in public health (for this subject read ESCCAP GL1).

*T. leonina* has a direct life cycle. Adult female worms in the small intestine produce eggs which are passed in the faeces to contaminate the environment. These eggs are thick-shelled and can survive in the environment for prolonged periods. Larvae develop within the eggs and ferrets are infected when they ingest eggs containing second stage larvae. Development occurs in the small intestine without migration. The pre-patent period is approximately 8 weeks. Infection with *T. leonina* and the other nematodes can be asymptomatic, or accompanied by abdomen enlargement, vomiting, diarrhoea and weight loss.

Heartworm (*Dirofilaria immitis*) is distributed across the world in tropical and subtropical climates. It is endemic in parts of southern Europe. The northern boundary of the endemic Mediterranean area is difficult to define, especially with the movement of pet animals across Europe, but an autochthonous case has been detected in Hungary. For further details, see ESCCAP Guideline No. 1: Worm Control in Dogs and Cats and ESCCAP Guideline 5: Control of Vector-Borne Diseases in Dogs and Cats.

Ferrets are as susceptible to heartworm infection as dogs and so adult worms can establish readily in infected animals. This is in contrast to cats where the number of worms establishing tends to be low. However, since a ferret’s heart and vessels are relatively small, even a small number of worms can cause severe illness. Infected ferrets can present with acute onset laboured breathing, which can be associated with anorexia, lethargy and cyanosis. Sudden death may occur and the presence of an adult worm infection is as life threatening for ferrets as it is in dogs and cats.



Diagnosis of mature patent heartworm infection can be carried out by demonstrating microfilariae in the blood using direct smears or the modified Knott's test (a more sensitive test as it concentrates the microfilariae by centrifugation so that they are easier to see during microscopic examination). However, this has limited use in the ferret as worms produce few microfilariae for a short period of time. More usefully, tests designed to detect heartworm antigens in dogs and cats are widely available and these tests have been shown to detect infections in ferrets from 4 months of age onwards, which is at least a month earlier than in dogs or cats. Filling defects caused by the presence of the worms can sometimes be very clearly seen using angiography. Radiography can also be a useful diagnostic test in ferrets for cardiomegaly, pleural effusion and ascites. Echocardiography is even more useful as this would reveal the dilated heart with the worm inside, which typically presents as two parallel running echogenic lines.

#### Tapeworm

Tapeworm infections are often asymptomatic but occasionally lead to anorexia, enteritis and weight loss.

#### Protozoa

Ferrets can be affected by a number of *Eimeria* species. Infection is, in all cases, transmitted by the ingestion of environmentally resistant oocysts that are passed in the faeces of infected ferrets. Infection is most likely to be a problem where large numbers of ferrets are kept intensively. Suitable conditions for oocyst survival can allow the build-up of high levels of environmental contamination. Infection is most likely to cause clinical signs in young ferrets but after an initial infection, they normally have a fairly strong acquired immunity. Intestinal coccidiosis can result in chronic diarrhoea, weight loss and reduced appetite.

*Giardia* spp. are flagellate protozoan parasites commonly found in the small intestine. Both trophozoites and cysts can be found in faeces. Trophozoites measure 12 x 5 µm and are attached to the mucous membrane of the intestinal villi. *Giardia* cysts can measure 8–10 µm. These parasites can be isolated through faecal examination using a zinc sulphate flotation technique. *Giardia* spp. can induce diarrhoea in young animals and if they belong to assemblage A, they may represent a zoonotic risk.

*Spironucleus muris* (syn. *Hexamita muris*) is a small pyriform flagellate (2–3 x 7–9 µm) and an inhabitant of the mid to lower small intestine of ferrets. It has been associated with clinical signs such as weight loss and diarrhoea.

*Tritrichomonas* spp. may be observed in fresh stool samples as motile protozoa with flagellae. They are not considered of pathogenic significance.

## EXTERNAL PARASITES

#### Fleas

The dog and cat fleas (*Ctenocephalides* spp.) are recognised as common ectoparasites of ferrets in Europe. Ferrets that are used for hunting wild rabbits may become infested with the rabbit flea *Spilopsyllus cuniculi*. These fleas attach around the pinnae and tend not to move even when handled. Fleas can cause allergic skin disease in ferrets and are capable, when present in sufficient numbers, of causing anaemia. It is, in addition, a zoonosis, with some humans developing severe reactions to flea bites.

#### Lice

Occasionally the dog louse *Trichodectes* spp. may infect ferrets.

#### Mites

*Sarcoptes scabiei* can infest ferrets and are found in pockets or burrows in the epidermis. The female measures 300–400 µm in length and the male around 250 µm. The cuticle is striated and grooved with small wedge-shaped scales. The eggs are laid in tunnels. Burrows are difficult to detect and just a few mites can cause considerable irritation, pruritus and lesions as in canine sarcoptic mange. This mite is easily transmitted through direct contact with other animals and in humans can cause skin irritation (scabies).

*Otodectes cynotis* (Fig. 26) is associated with otitis externa typified by an accumulation of brown wax in the external ear canal. Pruritus, head shaking and scratching may result in haematoma formation in the pinna of affected ferrets. Infection may be suspected on the basis of the history and clinical signs and can be confirmed by the demonstration of the mites in the affected area. *Otodectes cynotis* can be readily identified as the mites are about 0.5 mm in length and appear white against the brown wax of the affected ear.

*Ornithonyssus bacoti*, the blood-sucking tropical rat mite, has a worldwide distribution. Although typically a rat parasite, *O. bacoti* can also infest ferrets and few or no clinical signs may be observed. However, heavy infestations may result in anaemia and death.

*Demodex* mites (Fig. 27) are very uncommon in ferrets. Clinical signs are mostly associated with another primary cause of immune suppression (i.e. viral infections, diabetes, Cushing, corticosteroid treatments, neoplasia) and manifest as yellowish skin discoloration, local alopecia, seborrhoea and potentially also otitis externa with brownish exudate. Pruritus is not necessarily observed. The diagnosis is confirmed through deep skin scrapings.

#### Ticks

The ticks *Ixodes ricinus* and other Ixodidae can infest ferrets that have access to the outdoors or are used for hunting wild rabbits (Fig. 28). These ticks will feed for several days before they drop off naturally.

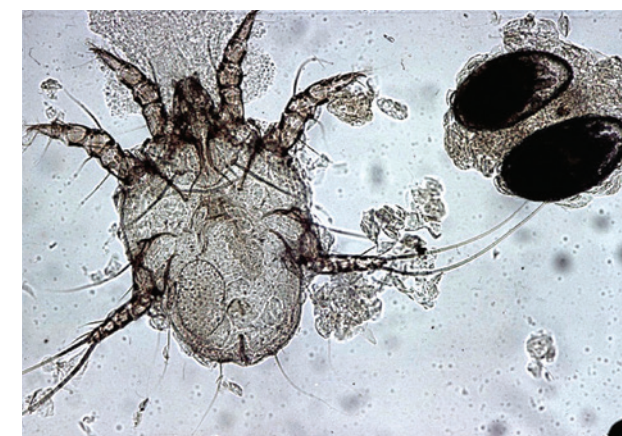


Fig. 26: *Otodectes cynotis* (one female and two eggs) 400x

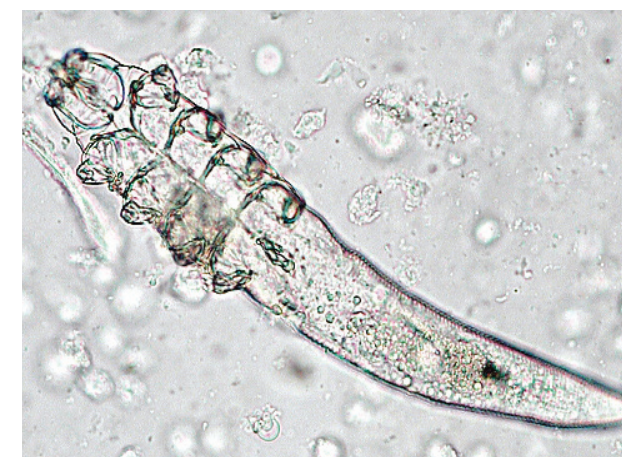

Fig. 27: *Demodex* spp.

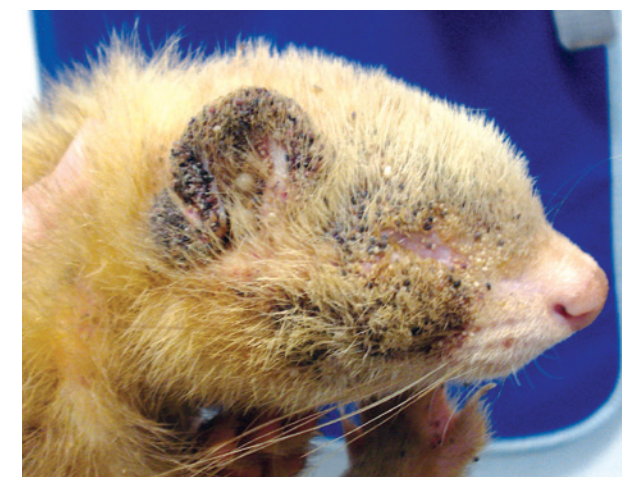


Fig. 28: Ticks on a ferret



## EXTERNAL FUNGAL INFECTIONS

*Trichophyton mentagrophytes* (complex species) and *Microsporum canis* appear to be the causative agents of dermatophytosis in ferrets in the majority of diagnosed cases. Transmission occurs through direct contact between animals or via a contaminated environment. Young animals are especially susceptible and are more likely to show clinical signs of infection (Fig. 29). Lesions begin as broken hairs with circular, scaly alopecia at the tip of the nose spreading to the periocular areas, forehead and ears. In severe cases, the sacrolumbar area is affected. Pruritus is minimal or absent. Some animals may show erythema, papules, pustules and crusts. Diagnosis is made by microscopic determination of arthrospores in skin scrapings (KOH method) or mycological cultures.

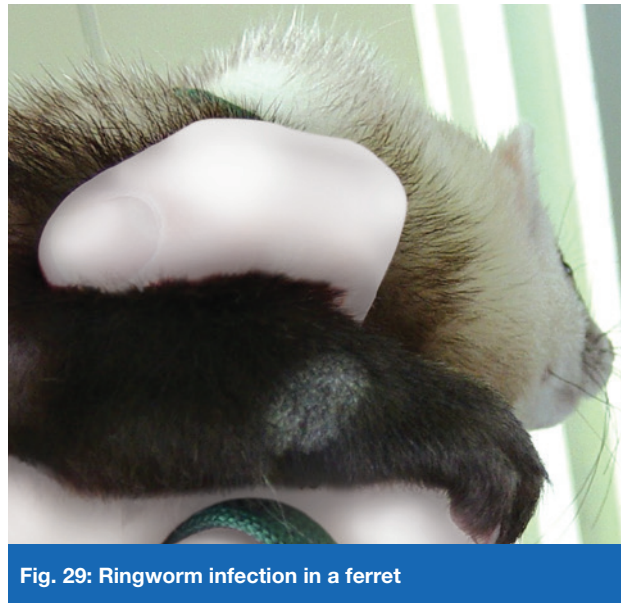


Fig. 29: Ringworm infection in a ferret

Ringworm is transmitted very easily by fungal spores on grooming equipment. If dermatophytosis is suspected, grooming equipment should not be used on any other animal. The spores are able to survive in the environment for years so after an outbreak, thorough disinfection is essential to kill the fungus. Dermatophytes are zoonotic and gloves should be worn when cleaning the environment and bedding should be burned to reduce the risk of transmission of infection.

## TREATMENT OF PARASITE AND FUNGAL INFECTIONS

There are only a few treatments available for parasitic infections in ferrets and almost all of them are used off-label.

### Roundworms

Gastrointestinal nematode infections can be treated orally with fenbendazole 20–50 mg/kg bodyweight daily for 3–5 days. Treatment with ivermectin 0.2–0.4 mg/kg bodyweight subcutaneously repeated after 14 days, or selamectin spot-on 6–15 mg/kg bodyweight at monthly intervals, may also be used.

As in dogs, treatment for heartworm infection in ferrets is complex. Under veterinary supervision, the same drugs used for the treatment of heartworm disease in dogs can be adapted for ferrets. Prevention and treatment of microfilariae with imidacloprid + moxidectin (0.1 ml of the small cat/kitten spot-on solution topically) is licensed for ferrets in some countries. Other treatment protocols include the use of ivermectin (0.05–0.1 mg/kg subcutaneously at monthly intervals until clinical signs have resolved and microfilaremia is no longer present), or the use of adulticides such as melarsomine (2.5 mg/kg intramuscularly followed by two injections at one-day intervals one month later) and thiacetarsamide (0.22 ml/kg intravenously twice daily for two days). Treatment for heartworm furthermore includes the use of symptomatic treatment to alleviate the clinical signs that result from the right-sided heart failure.

### Tapeworms

Tapeworms are treated with praziquantel (5–10 mg/kg bodyweight subcutaneously twice with a 10–14 day interval between treatments).

### Protozoa

Anticoccidial drugs (including trimethoprim + sulfonamide combinations) may be used in ferrets to treat coccidiosis including sulfadimethoxine, 50 mg/kg bodyweight orally followed by 25 mg/kg bodyweight once daily for 5–21 days.

As with all coccidial infections treatment should be accompanied by hygiene measures designed to reduce the possibilities of reinfection.

Metronidazole orally (15–20 mg/kg twice daily for 14 days or 50–75 mg/kg bodyweight daily for 5 days) or fenbendazole (10–20 mg/kg bodyweight orally for 5 days) may be administered to treat giardiasis. Rehydration may be needed especially in young animals and where diarrhoea is severe.

### Fleas

Apart from imidacloprid and fipronil, there is a shortage of approved treatments for fleas in ferrets. In some European countries, fipronil + S-methoprene is registered for treatment of fleas and ticks in dogs and this can be used in ferrets.

There are also numerous products that should be applied to the ferret's environment to aid flea control.

### Lice

Biting lice such as *Trichodectes* spp. can be treated with ivermectin (0.2–0.4 mg/kg bodyweight subcutaneously) repeated twice at weekly intervals or doramectin (0.5 mg/kg bodyweight subcutaneously) using the same protocol. Selamectin treatment (2–3 times with an interval of 14–30 days) or fipronil spray applied twice at intervals of 7–10 days have also been used. This is similar to the treatment described below for sarcoptic mange.

### Mites

Eradication of mites is always much more difficult to achieve in colonies than in individual animals. For mite-infected ferrets, ivermectin may be administered at 0.2–0.4 mg/kg bodyweight orally, repeated after 14 days. Spot-on treatments with selamectin (6–15 mg/kg bodyweight) and imidacloprid/moxidectin (1.9–3.3 mg/kg bodyweight) have also been recommended.

For the treatment of *Otodectes cynotis*, selamectin (15 mg spot-on) applied once has been shown to have good efficacy. Alternatively, 1–2 drops directly of fipronil into the ears, 0.5 mg/kg bodyweight ivermectin in each ear or 0.2–0.4 mg/kg bodyweight subcutaneously, all of which can be repeated after 14 days, are also effective. Before applying a topical treatment, ears should be cleaned with a mild antiseptic solution.

For the treatment of sarcoptic mange, different macrocyclic lactones have shown efficacy: ivermectin (0.2–0.5 mg/kg bodyweight subcutaneously) repeated twice at weekly intervals or doramectin (0.5 mg/kg bodyweight subcutaneously) using the same protocol have been recommended. Selamectin treatment (2–3 times 6–15 mg/kg bodyweight with an interval of 14–30 days) or fipronil spray applied twice at intervals of 7–10 days have also been used.

For the treatment of *Demodex* spp., amitraz washes (0.3% solution) or ivermectin (0.4 mg/kg bodyweight subcutaneously at weekly intervals or 0.05–0.3 mg/kg bodyweight daily until 1 month after negative skin scrapings) have been recommended.

### Ticks

Fipronil sprays are well tolerated. Alternatively, permethrin spot-on can be used (1–2 drops for animals below 400g or 3 drops for heavier animals).

## Fungal Infections

A combination of systemic and topical treatment is recommended. Systemic treatment relies on the daily administration of oral antifungal drugs: griseofulvin (25–50 mg/kg bodyweight – this can be given in two daily doses), itraconazole (15–30 mg/kg bodyweight) or terbinafine (8–20 mg/kg bodyweight). The decision to use topical therapy (with enilconazole 0.2% or miconazole) should be based upon the owner's ability and willingness to pour or sponge the product over the entire coat of the infected animal. The frequency of topical treatment should be at least twice a week. When sponging or bathing, the owner needs to consider hypothermia and the animal should be dried carefully. Miconazole ointment or cream can also be used on localised lesions but on a daily basis.

Hygiene measures are extremely important, especially treatment of the environment. For large groups of affected ferrets, the environment can be sprayed with an enilconazole solution of 50 mg/m<sup>2</sup> twice weekly for 4 months. Additionally, the ferret owner should use disposable gloves and thoroughly wash/disinfect clothes and shoes after every treatment and/or animal manipulation.

## PREVENTION OF PARASITE AND FUNGAL INFECTIONS

Prevention of parasite infection generally involves a combination of good environmental management and prophylactic drug treatments.

For example, quarantine should be initiated for animals of unknown history before mixing with resident animals and high standards of husbandry should be maintained with particular attention to feed and bedding. Dogs with access to areas frequented by ferrets should be regularly treated for tapeworms to avoid infecting the ferrets with tapeworm cysts.

Quarantine measures should be put in place for all animals of unknown health history joining a resident individual or group. Feed, hutches and bedding should always be kept clean and high standards of hygiene should be observed.

Heartworm disease in endemic areas can be prevented by prophylactic topical administration of moxidectin (0.1 ml topically of the small cat/kitten spot on solution), selamectin (18 mg/kg bodyweight topically), ivermectin (0.05 mg/kg bodyweight orally or subcutaneously) or milbemycin oxime (1.15–2.33 mg/kg bodyweight orally) at monthly intervals.

### **Disclaimer:**

Every effort has been taken to ensure that the information in the guideline, which is based on the authors' experience, is accurate. However the authors and publishers take no responsibility for any consequence arising from the misinterpretation of the information herein nor is any condition or warranty implied. ESCCAP emphasises that national, regional and local regulations must be borne in mind at all times before following ESCCAP advice. All dosages and indications are provided for guidance. However, vets should consult individual data sheets for details of locally approved treatment regimens.

## APPENDIX 1 – BACKGROUND

ESCCAP (European Scientific Counsel Companion Animal Parasites) is an independent, not-for-profit organisation that develops guidelines and promotes good practice for the control and treatment of parasites in companion animals. With the proper advice the risk of diseases and parasitic transmission between animals and humans can be minimised. ESCCAP aspires to see a Europe where companion animal parasites no longer threaten the health and well-being of animals and humans.

There is a great diversity in the range of parasites and their relative importance across Europe and the ESCCAP guidelines summarise and highlight important differences which exist in different parts of Europe and, where necessary, specific control measures are recommended.

### **ESCCAP believes that:**

- Veterinarians and pet owners must take measures to protect their pets from parasitic infestations.
- Veterinarians and pet owners must take measures to protect the pet population from risks associated with travel and its consequent potential to change local parasite epidemiological situations through the export or import of non-endemic parasite species.
- Veterinarians, pet owners and physicians should work together to reduce the risks associated with zoonotic transmission of parasitic diseases.
- Veterinarians should be able to give guidance to pet owners regarding risks of parasite infestation and diseases, and measures which can be taken to minimise these risks.
- Veterinarians should attempt to educate pet owners about parasites to enable them to act responsibly not only for their own pet's health but for the health of other pet animals and people in their communities.
- Veterinarians should wherever appropriate undertake diagnostic tests to establish parasite infestation status in order to provide the best possible advice.

### **To achieve these objectives, ESCCAP produces:**

- A detailed guideline for veterinary surgeons and veterinary parasitologists.
- Shorter summarised or adapted guidelines which can be used by both veterinarians and pet owners.
- Versions of each guideline can be found at [www.esccap.org](http://www.esccap.org)

## IMAGE ACKNOWLEDGEMENTS

ESCCAP would like to thank the following for permitting their images to be reproduced within this guideline:

- Christophe Bulliot (DVM, Nandy, France)
- Cristina Almeida (DVM, Algés, Portugal)
- Department Infectious Diseases and Immunology, Faculty of Veterinary Medicine, Utrecht University
- Department Parasitology, École nationale vétérinaire d'Alfort (EnvA, Maisons-Alfort, France)
- John McGarry and School of Veterinary Science, University of Liverpool
- Luís Madeira de Carvalho (Faculty of Veterinary Medicine, University of Lisbon)
- N. J. Schoemaker (Faculty of Veterinary Medicine, Utrecht University)
- Y. R. A van Zeeland (Faculty of Veterinary Medicine, Utrecht University)



ISBN: 978-1-907259-39-5

ESCCAP Secretariat  
Malvern Hills Science Park, Geraldine Road, Malvern,  
Worcestershire, WR14 3SZ, United Kingdom

Tel: +44 (0) 1684 585135  
esccap@btinternet.com  
[www.esccap.org](http://www.esccap.org)



## **7** Control of Parasites and Fungal Infections in Small Pet Mammals

ESCCAP Guideline 07 First Edition – July 2017